

# Healing oxygen

Oxygen has been used in dentistry for the last decade. The first use was to bleach teeth. To achieve this effect, the oxygen was bound in the toothpastes, which resulted in the so-called whitening toothpastes coming onto the market. An interesting side effect of this was the reduction of periodontal problems among people who used these toothpastes. This remarkable phenomenon attracted attention and led to the development of a therapeutic gel. **By Pieter Willem Krijnen**

**I**NITALLY OXYGEN WAS PRIMARILY USED ON A more experimental basis in cases involving more major maxilla reconstructions with pelvic bone. This is done by taking a piece of bone from the crista iliaca and inserting it into the atrophic maxilla. With these reconstructions, bone loss was a frequent occurrence due to dehiscences and necrosis of the exposed bone. In attempts to counter this bone loss, the oxygen gel was used. This turned out to be very effective. It was noticeable that there were fewer complications and that the healing process proceeded faster.

Since this first successful use, improvements have been made to the composition of the gel and an oxygen-containing liquid has also been developed. The oxygen was manufactured in a more precise manner and prepared for various uses.

The explanation for the efficacy of the gel stems from research into the effects of oxygen on tissues and bacteria. In particular the studies conducted into the use of the hyperbaric oxygen tank and the effects of oxygen on anaerobic bacteria support the efficacy of the gel and the liquid.

This ushered in a new era.

## Action

The use of the hyperbaric oxygen tank is one use that is much studied in the medical field.

---

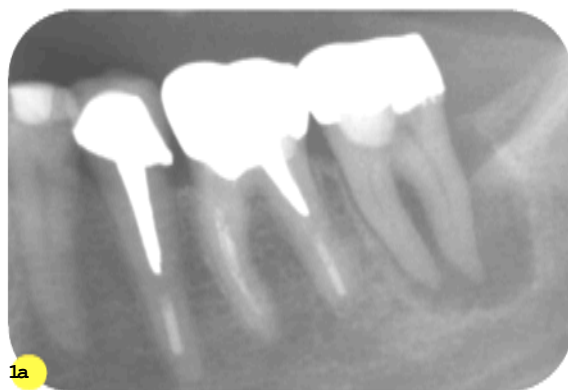
**Pieter Willem Krijnen** is a dentist working in the Beekmans dental practice in Laren. In his work he focuses on implantology and aesthetic dentistry.

Oxygen ensures:

- neovascularisation
- the elimination of toxins
- stimulation of the formation of new blood cells
- an increase in the production of stem cells
- faster healing
- the eradication of bacteria.

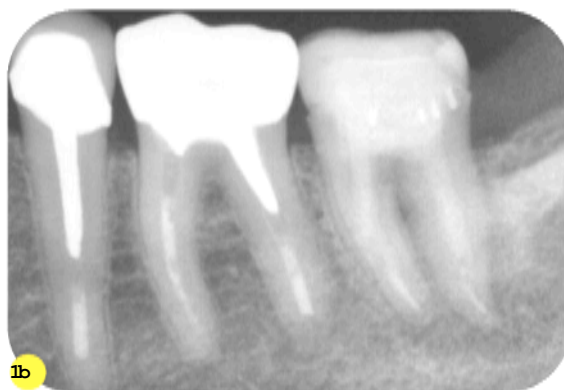The idea that oxygen can be stored in a gel or liquid is a relatively new concept for the medicine. It is therefore an application that is still only used to a limited extent in medicine and dentistry.

The action of oxygen is based on a sodium perborate (the exact formula is a trade secret) where oxygen is released. The quantity that is thus produced is a low concentration, which is therapeutic for the body. This is in contrast to e.g. chlorhexidine (CHX). A recently published study in the latter warned about changes to the DNA structure



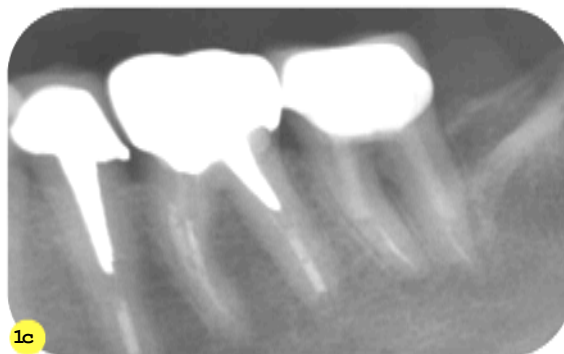
1a

**Image 1a** Solo 2007. Element 37 with large periapical radiolucency, endo only flushed with blue oxygen fluid.



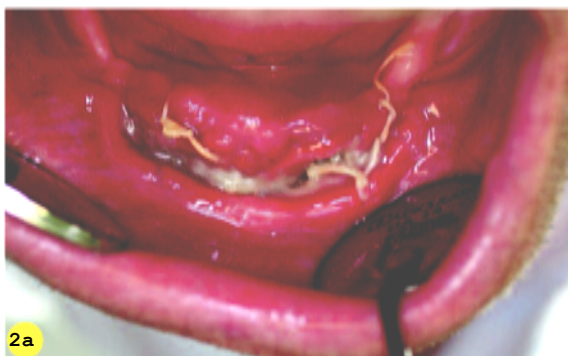1b

**Image 1b** Solo 2008. Bone ingrowth perceptible.



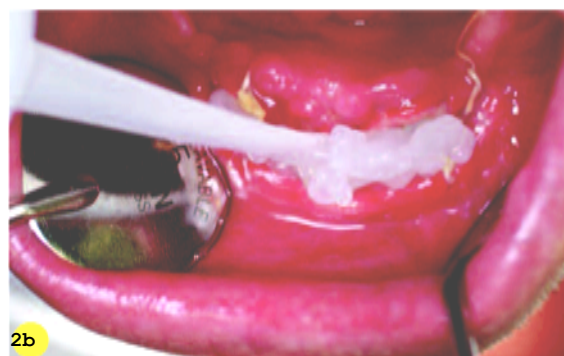
1c

**Image 1c** The x-ray picture shows an image that fits full healing.



2a

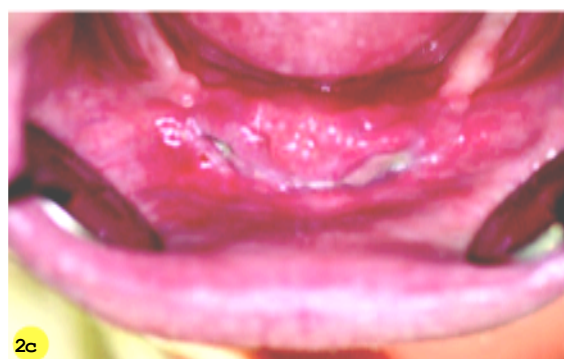**Image 2a** Dehiscence 1 week after performing an Edlan-plasty for the benefit of implantology.



2b

**Image 2b** Application of blue oxygen gel (higher concentration) with monoject directly on the dehiscence.

**Image 2c** Healing has started two weeks after application of the gel without additional antibiotic.



2c

in tissues of the oral mucosa in animal tests.

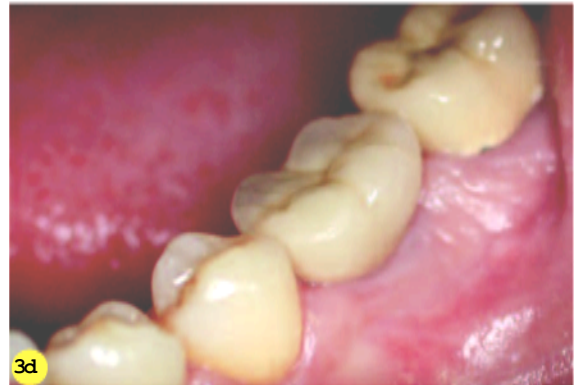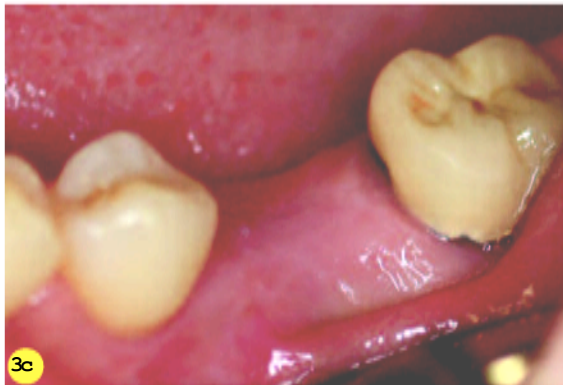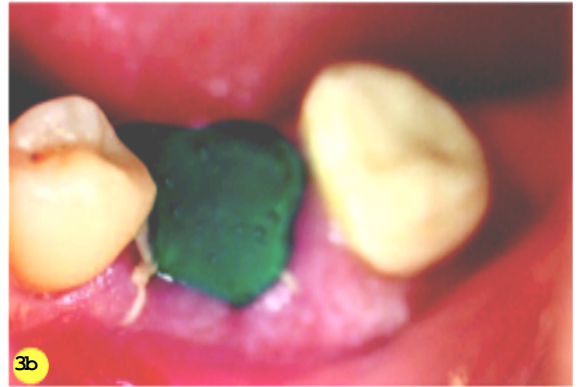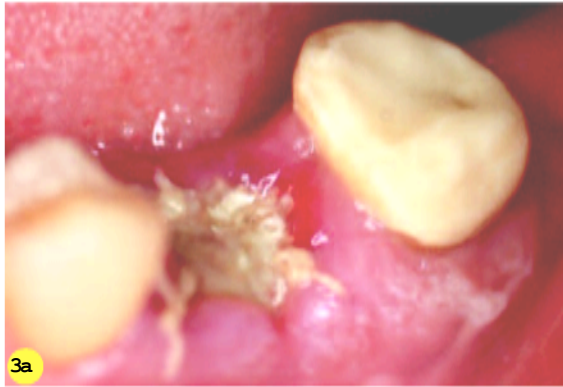In addition to the peroxide-containing component, there are also other substances in the gel and the liquid that have an antibacterial action. For example, for the creation of a relatively low pH, making it easier to release the oxygen bound to haemoglobin. The antibacterial effect is attributed, among other matters, to the increased osmotic value.

In a delicate environment such as the mouth we certainly cannot be careful enough and the use of oxygen is one way to promote wound healing, without the use of chlorhexidine with all its disadvantages (black tongue, skin irritations).

## Applications

Oxygen processed into a gel or a liquid can be applied in:

- implantological, periodontal, endodontic and general surgery
- endodontic treatments (use of the liquid instead of sodium hypochlorite)

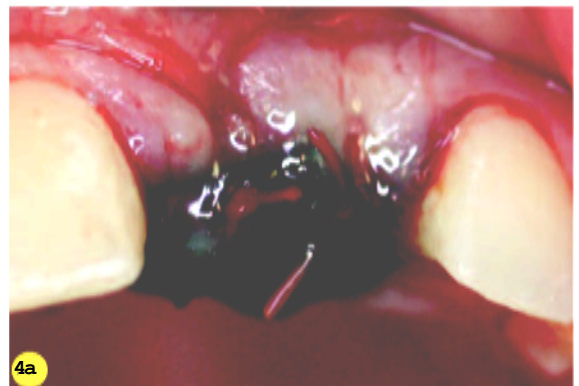

**Image 3a** Irritated image after extraction.

**Image 3b** Application of blue oxygen paste (lower concentration).

**Image 3c** Clinical image 4 weeks after applying the oxygen paste.

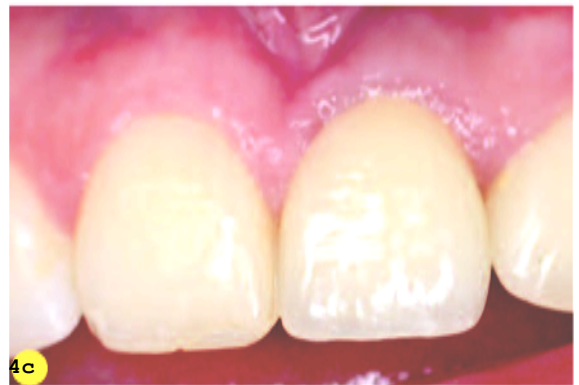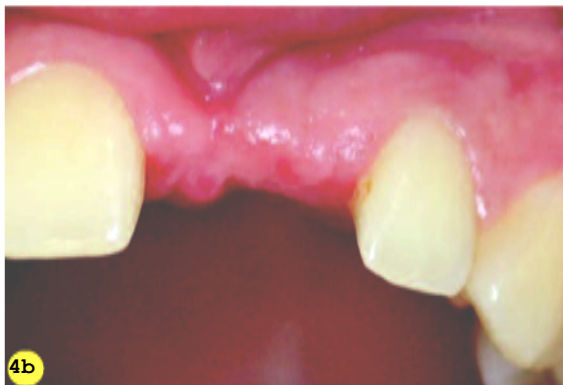**Image 3d** A few months after placing the crown on the implant



**Image 4a** The insertion of a buccal bone plate at the location of the 21, with blue oxygen gel and without additional antibiotic.

**Image 4b** Image 2 months after the operation shows the gingiva have completely healed.

**Image 4c** Immediately after placing the crown it can be seen that the gingiva is still slightly irritated at that spot, but that the rest of the gingiva are quiescent.



- treatment of mouth ulcers
- irritations due to recently commenced orthodontic treatments
- burns
- cuts and grazes
- necroses
- decubitus

- psoriasis
- fungal infections
- parodontal abscesses
- peri-implantitis