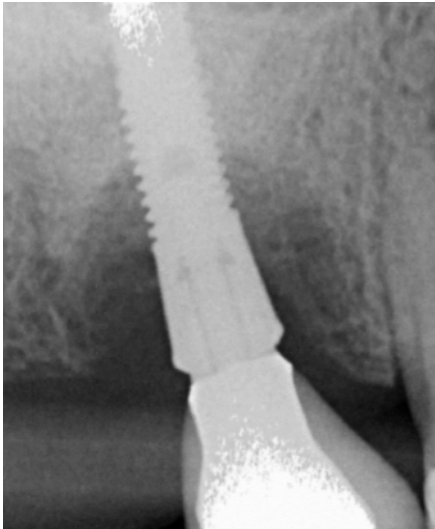


BlueM, for the protection of injured periodontal tissue

Peri-implantitis

2016: Nijmegen The Netherlands



BlueM, for the protection of injured periodontal tissue

Maïke Prick-Huisman, Nijmegen, the Netherlands.
Dentist.



- After graduating I started a career as a professional horse trainer. I am a multiple dutch champion in reining and other western disciplines and finished fourth at the European championship in youth reining.
- In 2004 I started my education as a dentist at the Radboud University Nijmegen. Graduated in 2009.
- 2009-2012 Working for several clinics
- 2010-2013 The Centre of specialized dentistry at The Radboud University.
- 2013 until now: Owner dental practice h2 tandartsen Nijmegen.

BlueM, for the protection of injured periodontal tissue

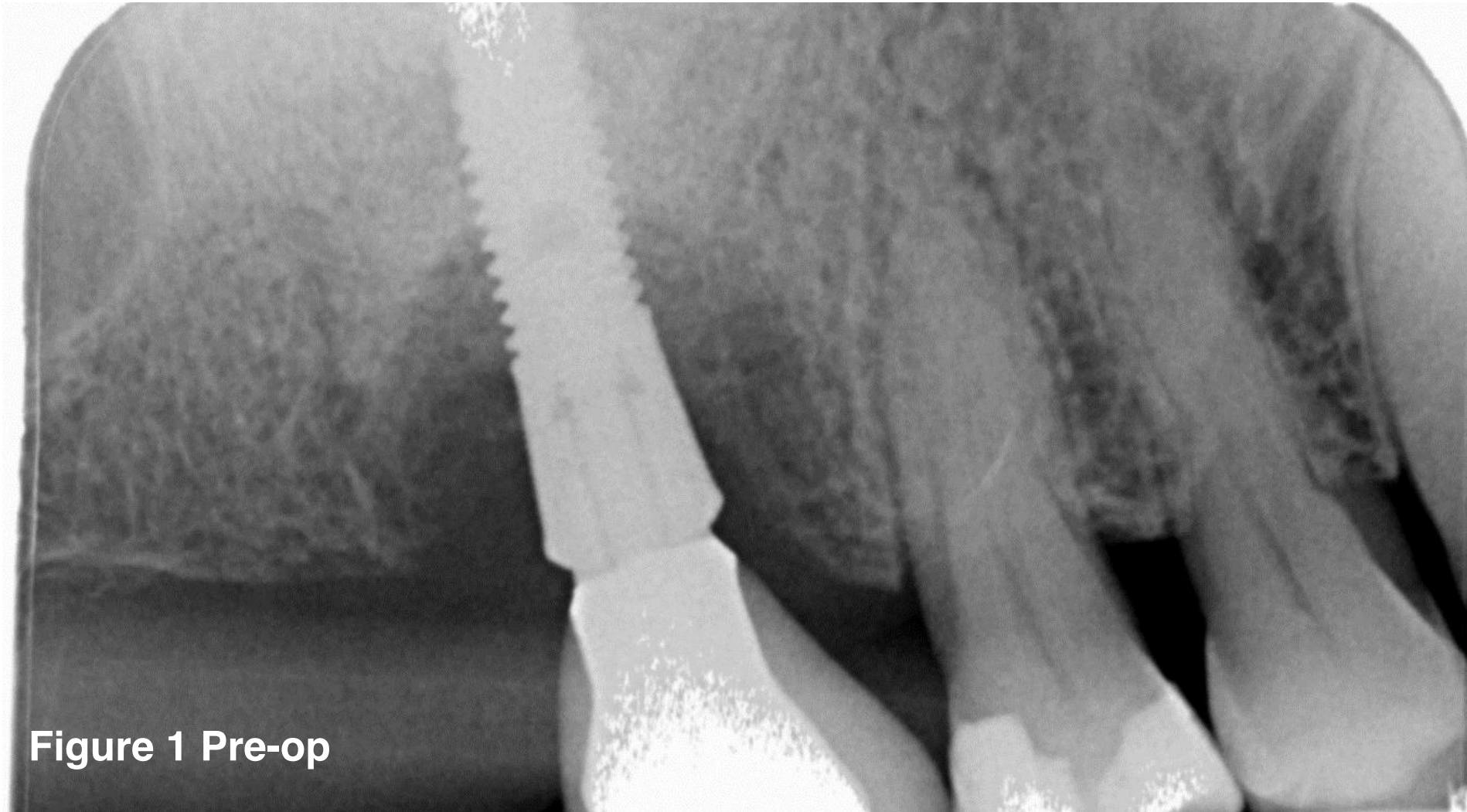


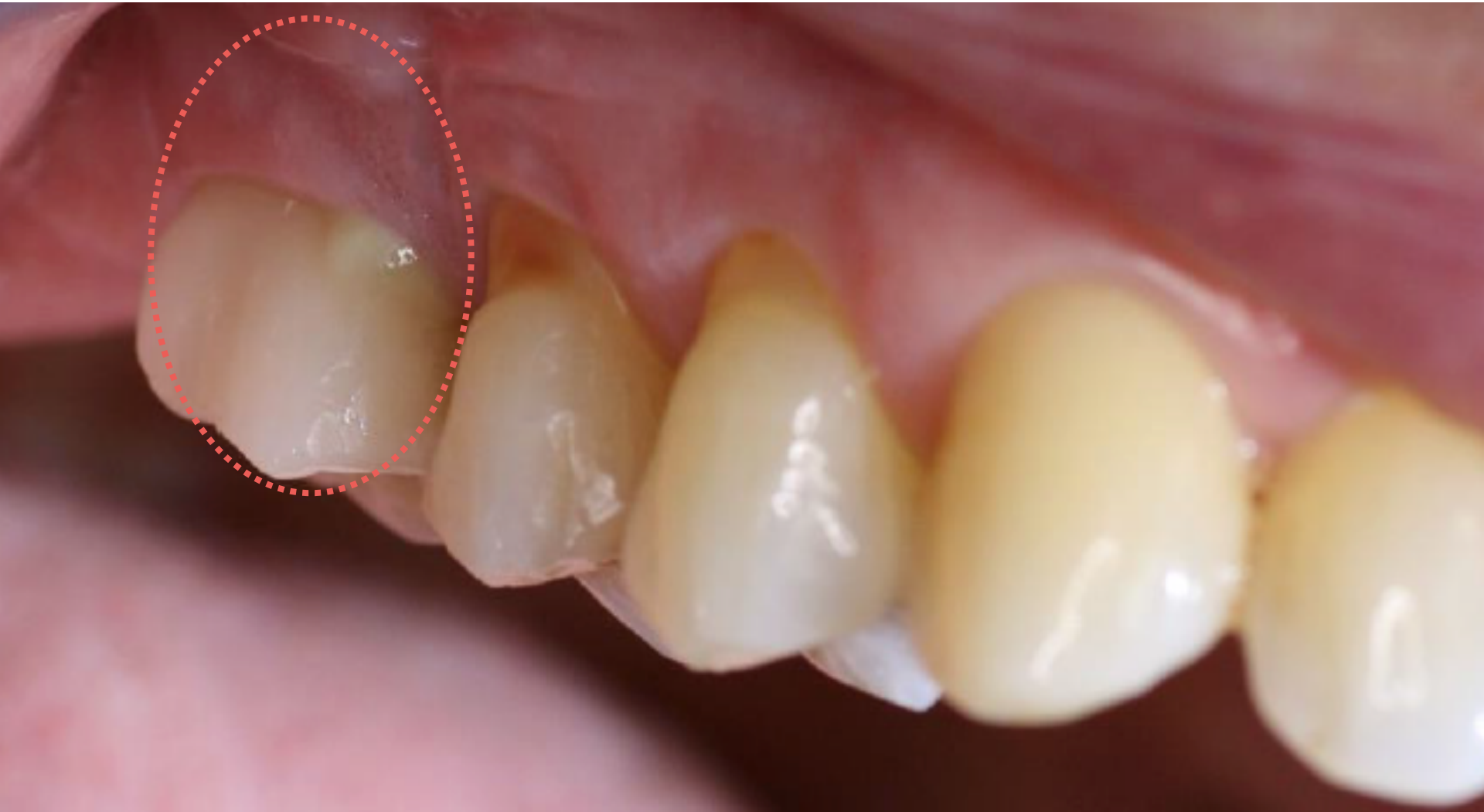
Figure 1 Pre-op

BlueM, for the protection of injured periodontal tissue

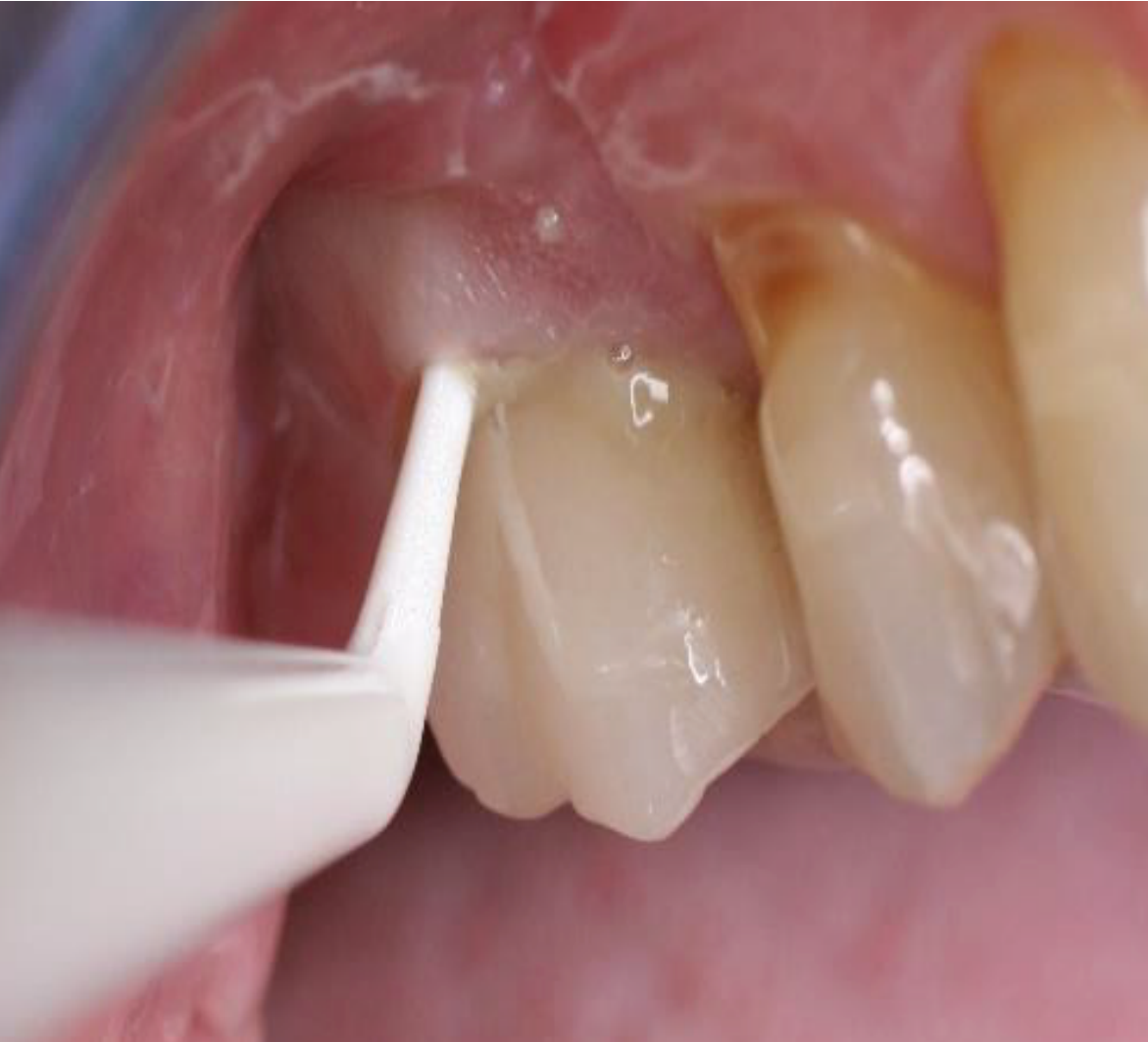Peri-implantitis 1.6

- Patient came to my practice with complaints around implant (1.6.)
- Upon probing (measuring the depth of the infection) we find a 10mm pocket.
- Symptoms included tender and painful gums, odor, pus coming out from all areas around the implant.
- First we have tried to improve the situation with BlueM oral gel, BlueM toothpaste and BlueM mouthwash only 2 times daily.
- Finally decided for a flap surgery.

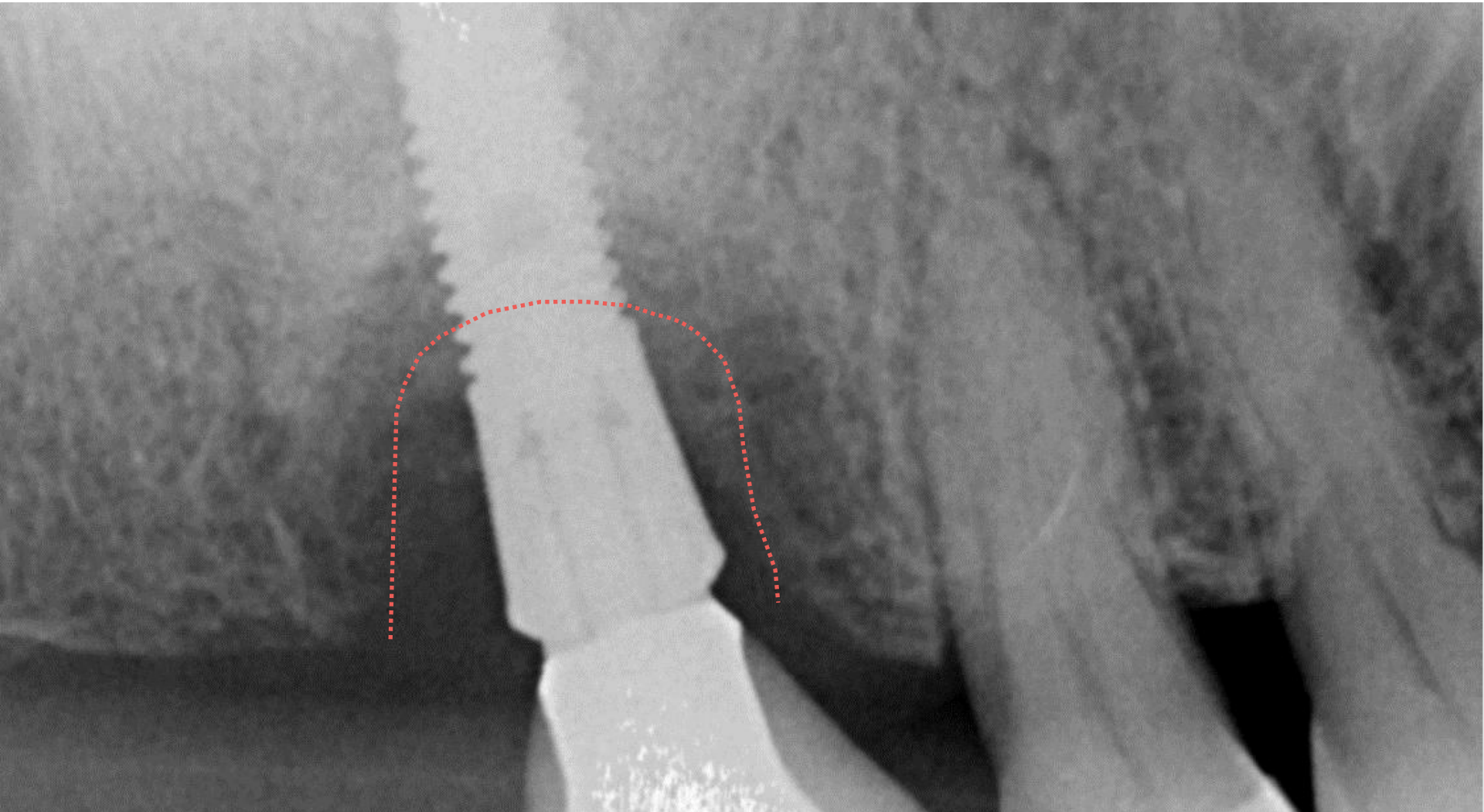
BlueM, for the protection of injured periodontal tissue



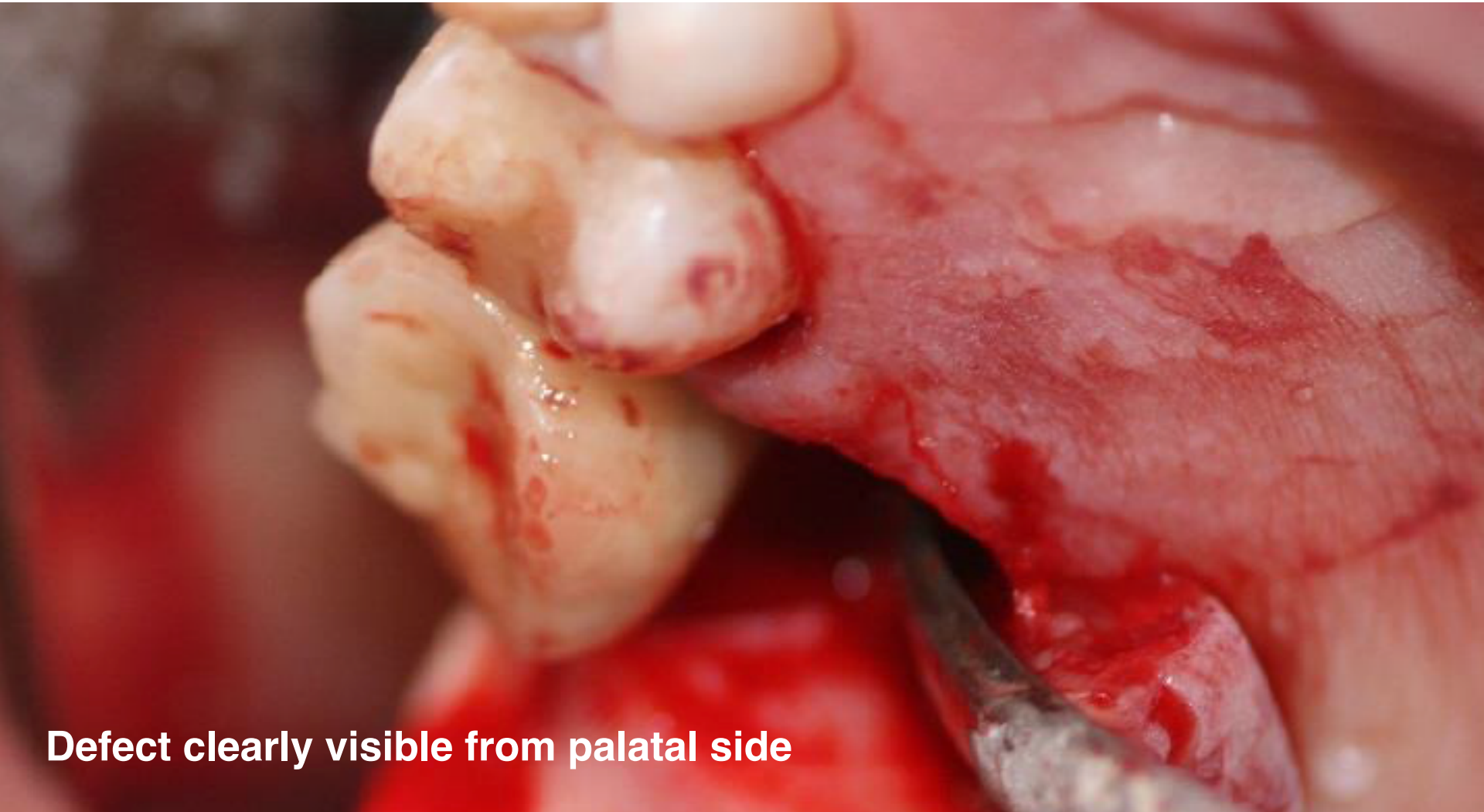BlueM, for the protection of injured periodontal tissue



BlueM, for the protection of injured periodontal tissue



BlueM, for the protection of injured periodontal tissue



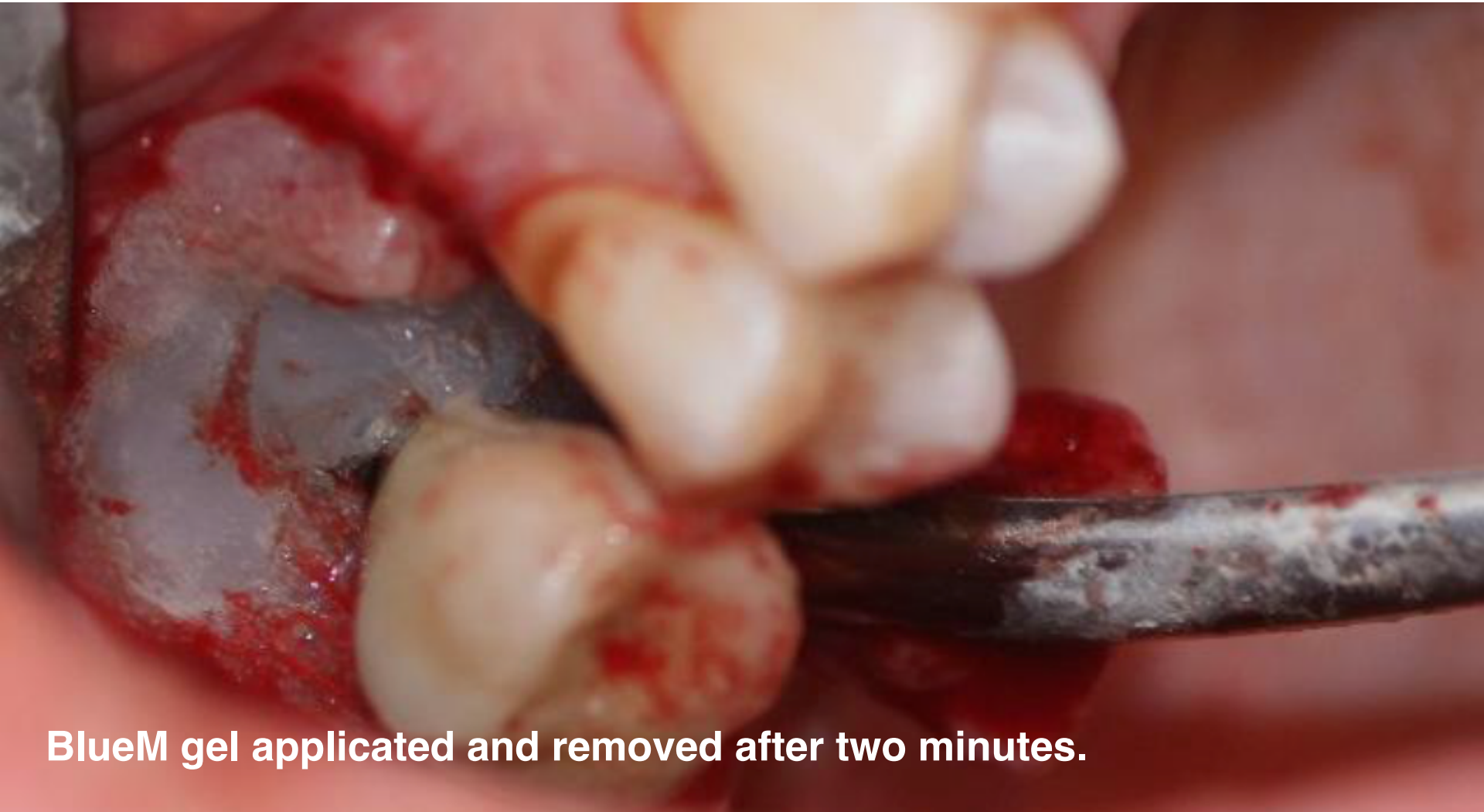Defect clearly visible from palatal side

BlueM, for the protection of injured periodontal tissue

Flap surgery

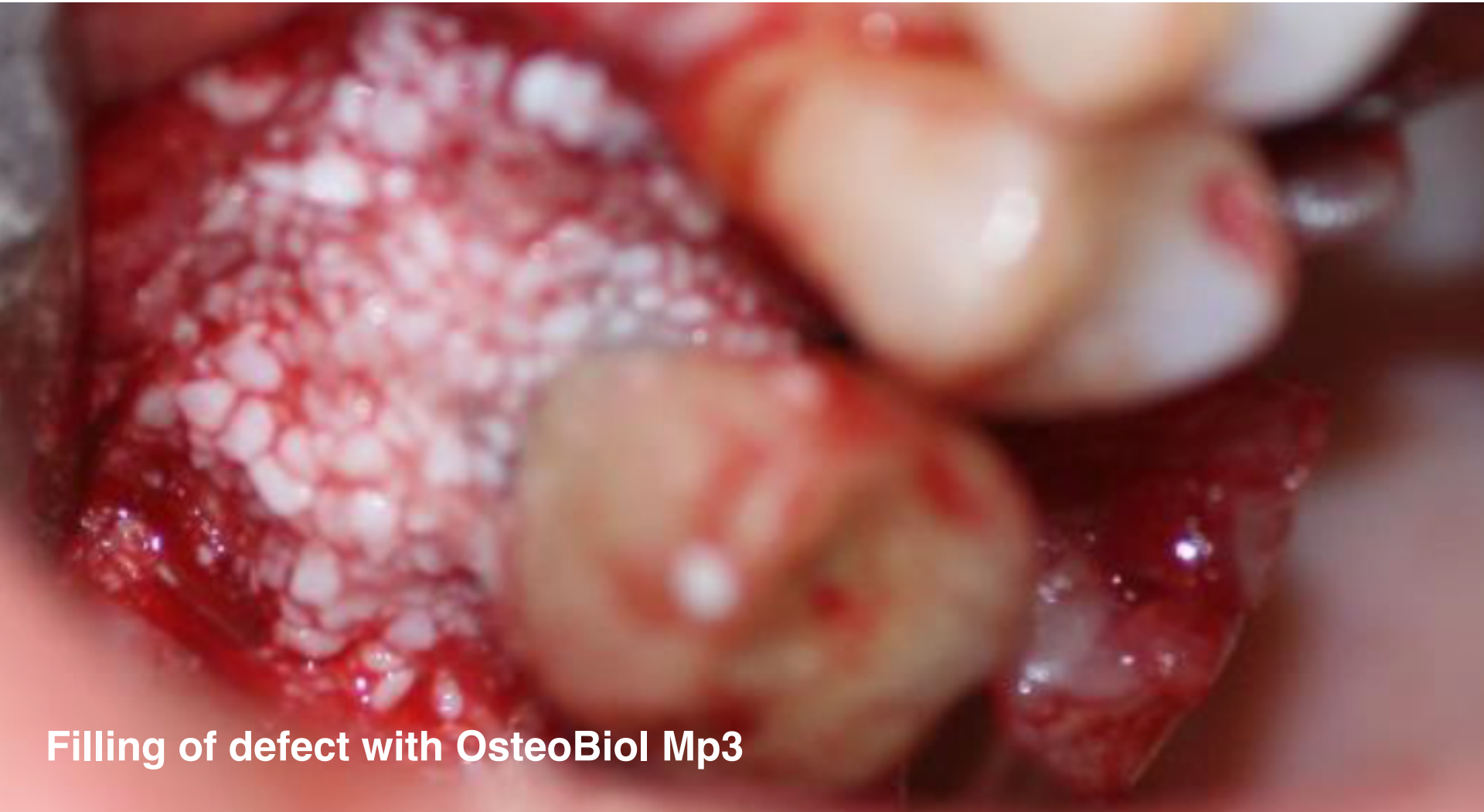- By incision a lot of pus
- Many granulation tissue.
- Wound cleaned and inflamed tissue removed.
- Implant cleaned with EMS perio airflow.
- BlueM gel applied and removed after two minutes.
- Filling of defect with OsteoBiol Gen-Os
- Placement of OsteoBiol membrane to protect the defect and to cover the grafted material.
- Stitched and wound covered with BlueM oral gel.
- Recall patient after one week.

BlueM, for the protection of injured periodontal tissue



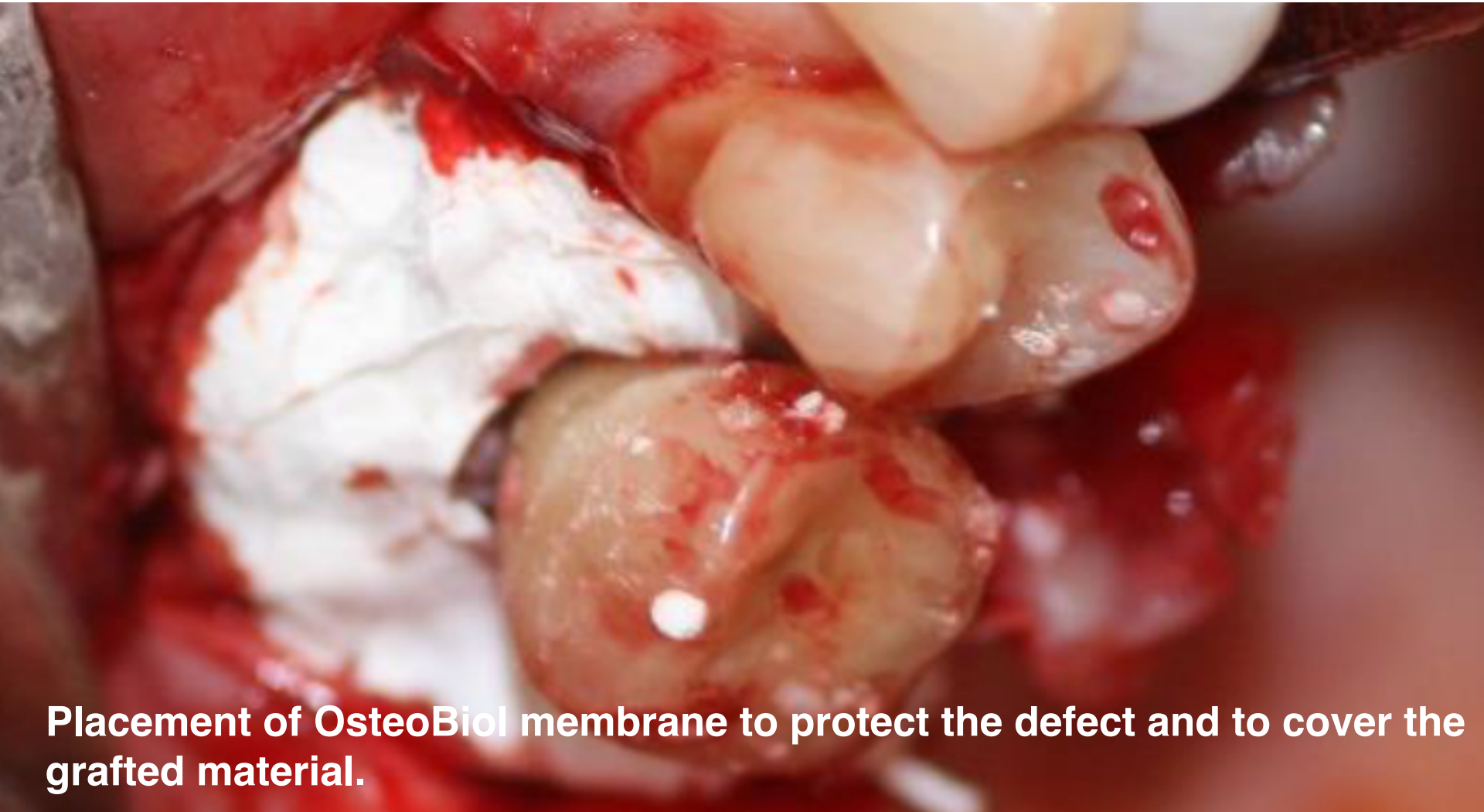BlueM gel applied and removed after two minutes.

BlueM, for the protection of injured periodontal tissue



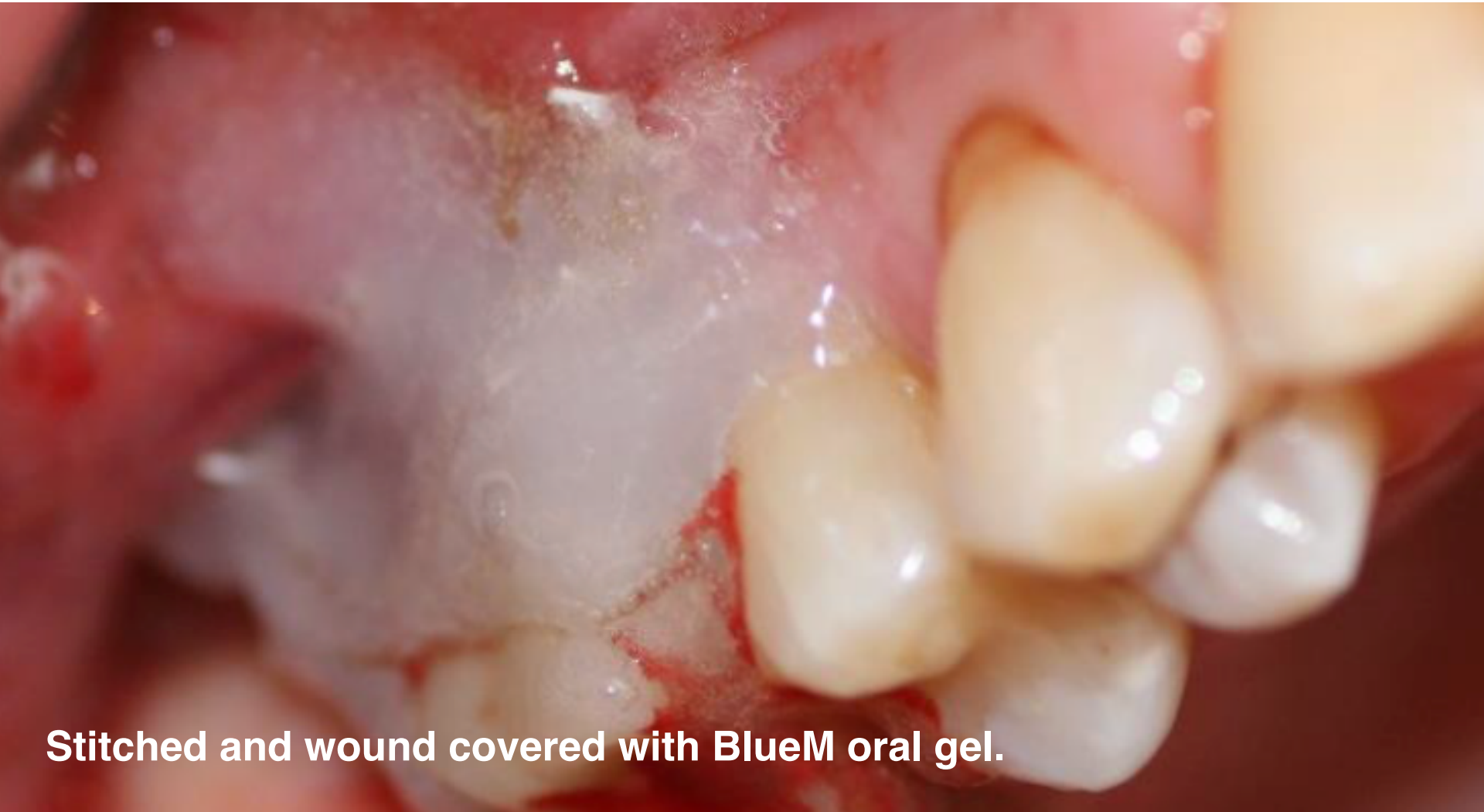Filling of defect with OsteoBiol Mp3

BlueM, for the protection of injured periodontal tissue



Placement of OsteoBiol membrane to protect the defect and to cover the grafted material.

BlueM, for the protection of injured periodontal tissue



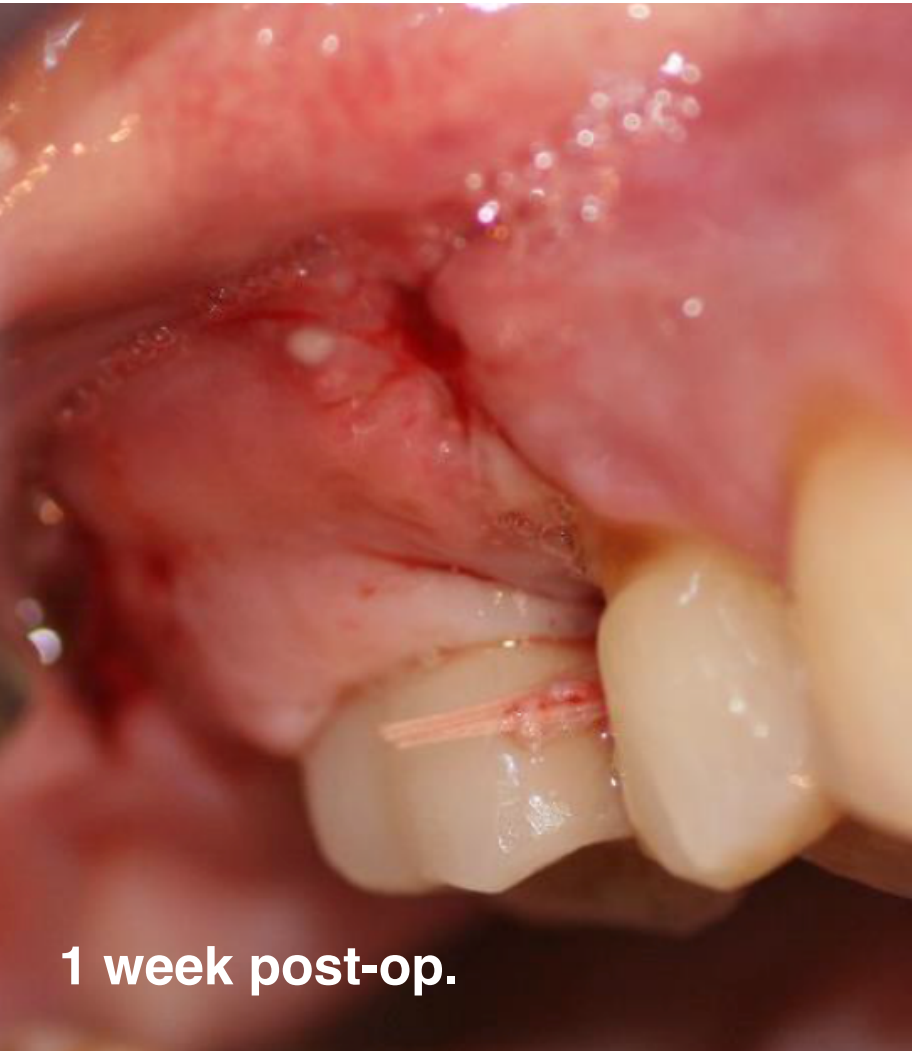Stitched and wound covered with BlueM oral gel.

BlueM, for the protection of injured periodontal tissue

Flap surgery

- After one week:
- Region still slightly swollen.
- Wound is healing.
- Mesial a suture placed for extra support.
- BlueM oral gel is applicated by patient with interdental brush.
- Recall after 2 weeks.

BlueM, for the protection of injured periodontal tissue



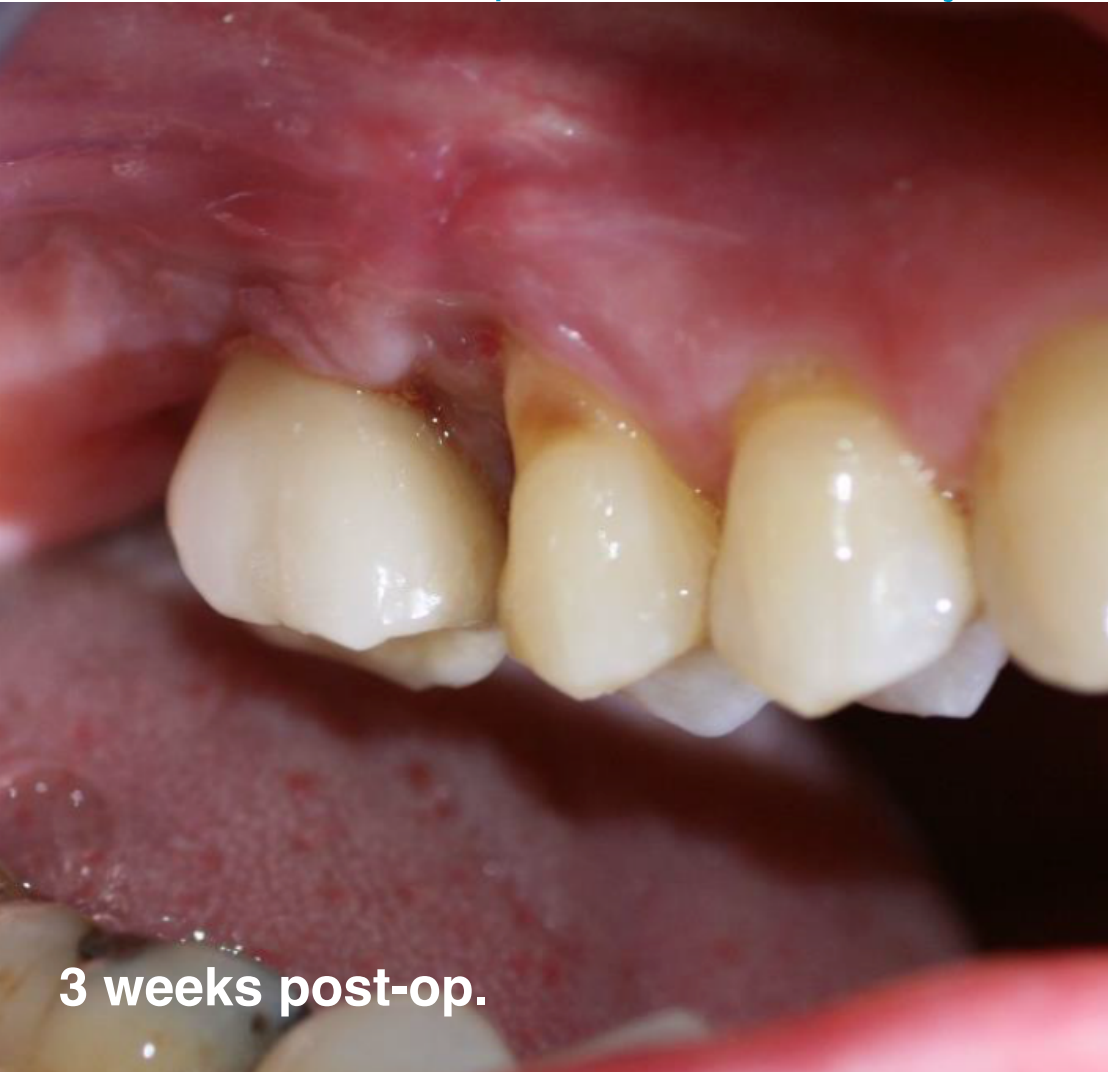1 week post-op.

BlueM, for the protection of injured periodontal tissue

Flap surgery

- After three weeks:
- Greatly improved situation. Daily use of BlueM toothpaste & BlueM mouthwash
- Small loss of bone granules.
- Stitches removed completely.
- Recall after 1 month.

BlueM, for the protection of injured periodontal tissue



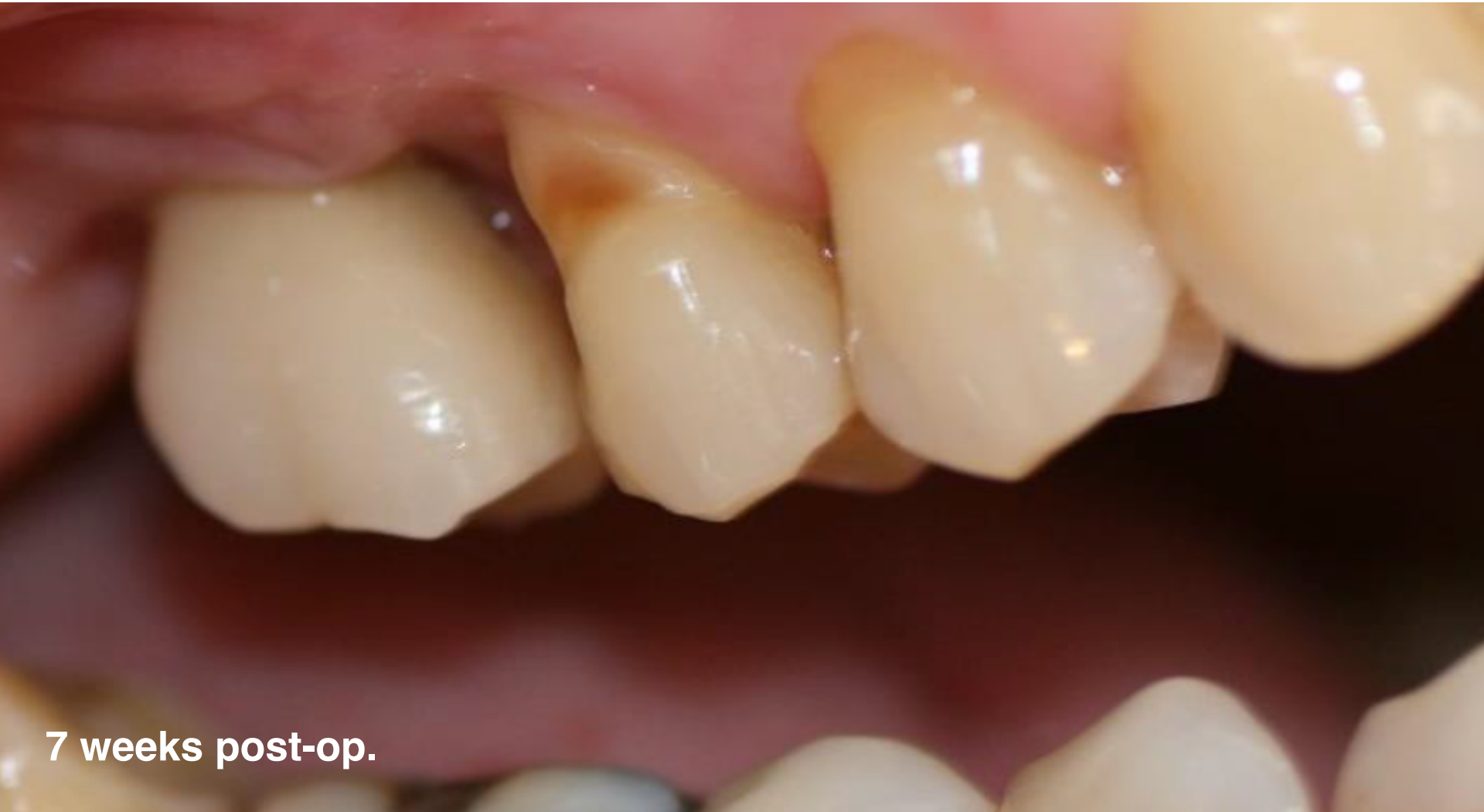3 weeks post-op.

BlueM, for the protection of injured periodontal tissue

Flap surgery

- After seven weeks:
- Still daily use of BlueM oral gel applied with interdental brush.
- Daily use of BlueM toothpaste and BlueM mouthwash.
- No bleeding during probing.
- Gingiva may come down a bit more cervical.
- Recall after 3 months.

BlueM, for the protection of injured periodontal tissue



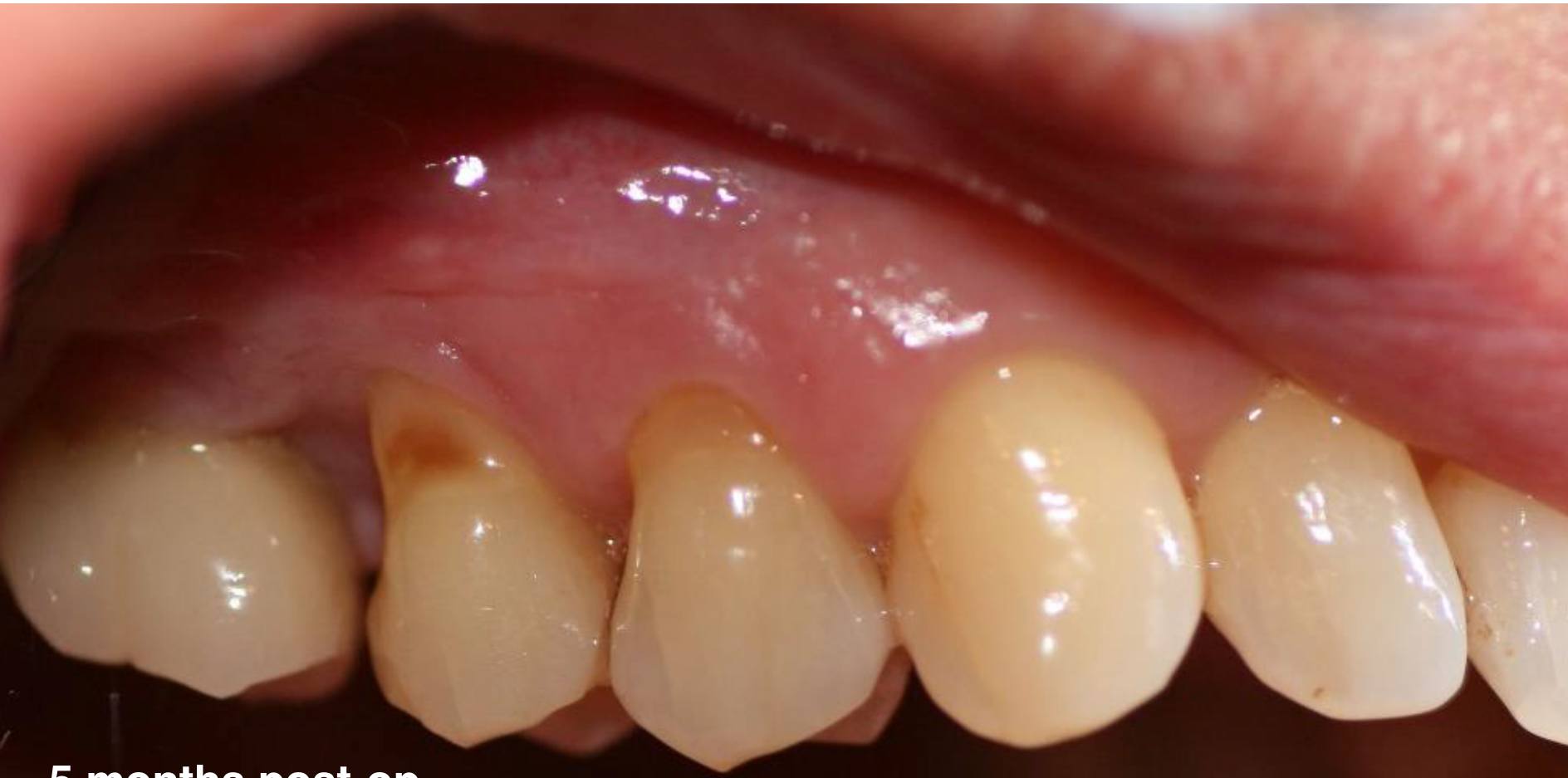7 weeks post-op.

BlueM, for the protection of injured periodontal tissue

Flap surgery

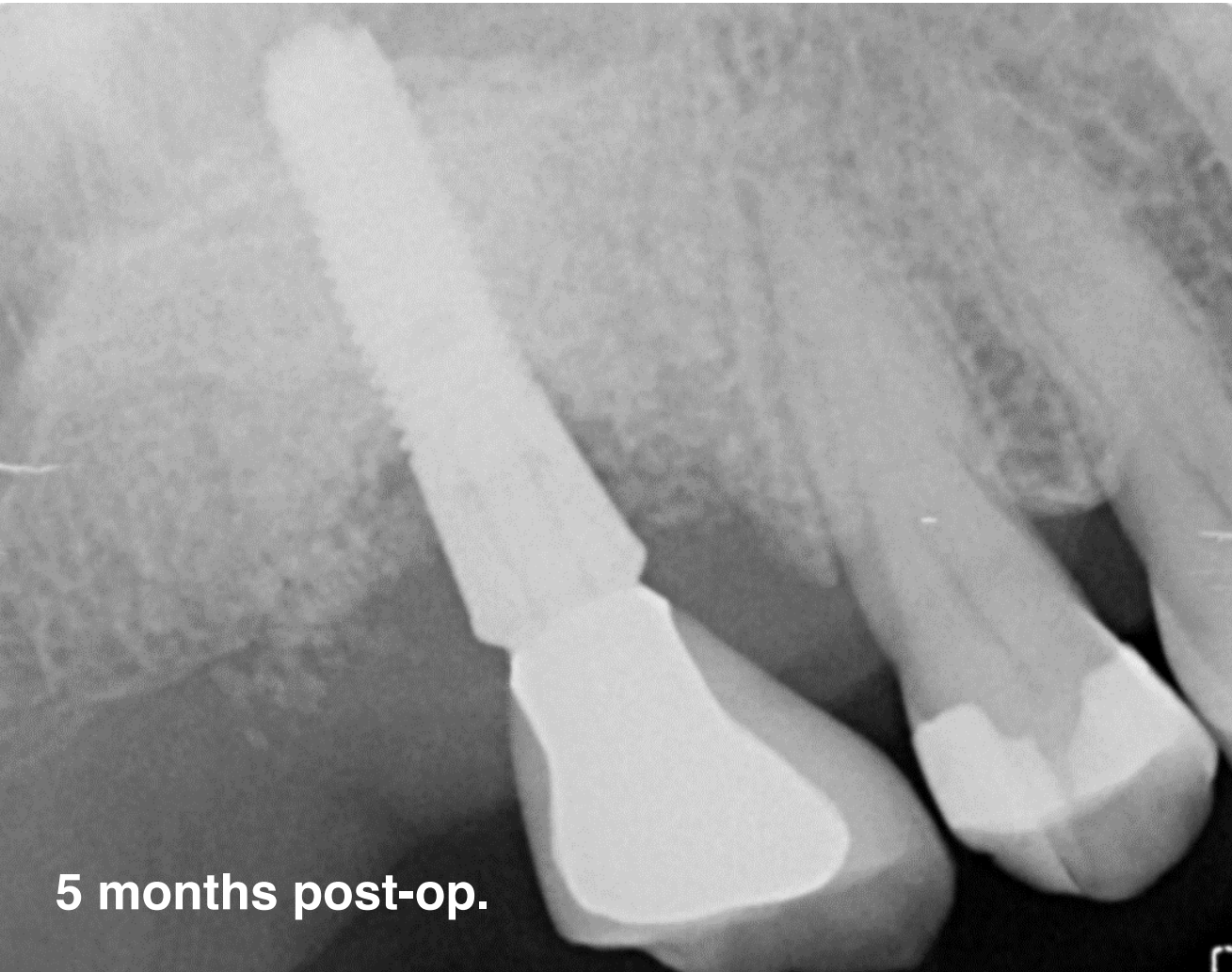- After 5 months:
- Gum recession further repaired
- Patient had stopped using the interdental brush and we advised the patient to start using the interdental brush with BlueM oral gel again.
- X-ray made, bone /artificial bone at normal height.
- Gingiva may come down a bit more cervical.
- Recall after 6 months to see the dentist. Patient visit oral hygienist every three months.

BlueM, for the protection of injured periodontal tissue



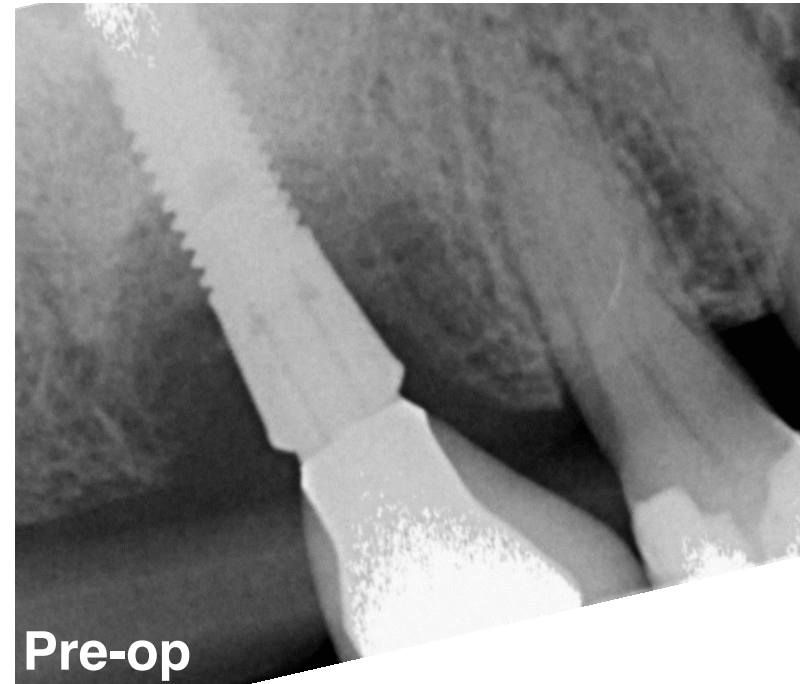
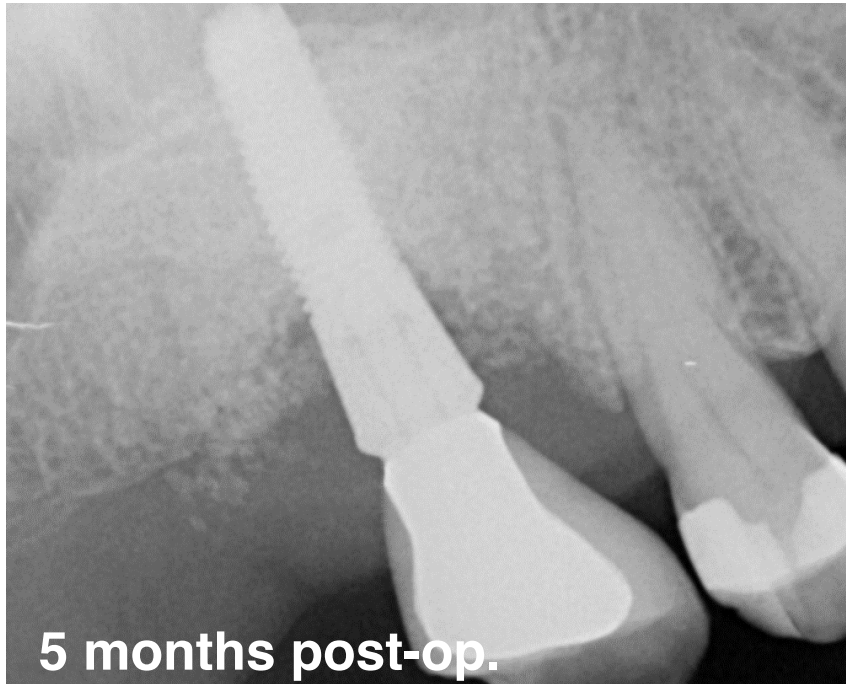5 months post-op.

BlueM, for the protection of injured periodontal tissue



5 months post-op.

BlueM, for the protection of injured periodontal tissue



BlueM, for the protection of injured periodontal tissue

Clinical situation before & after

