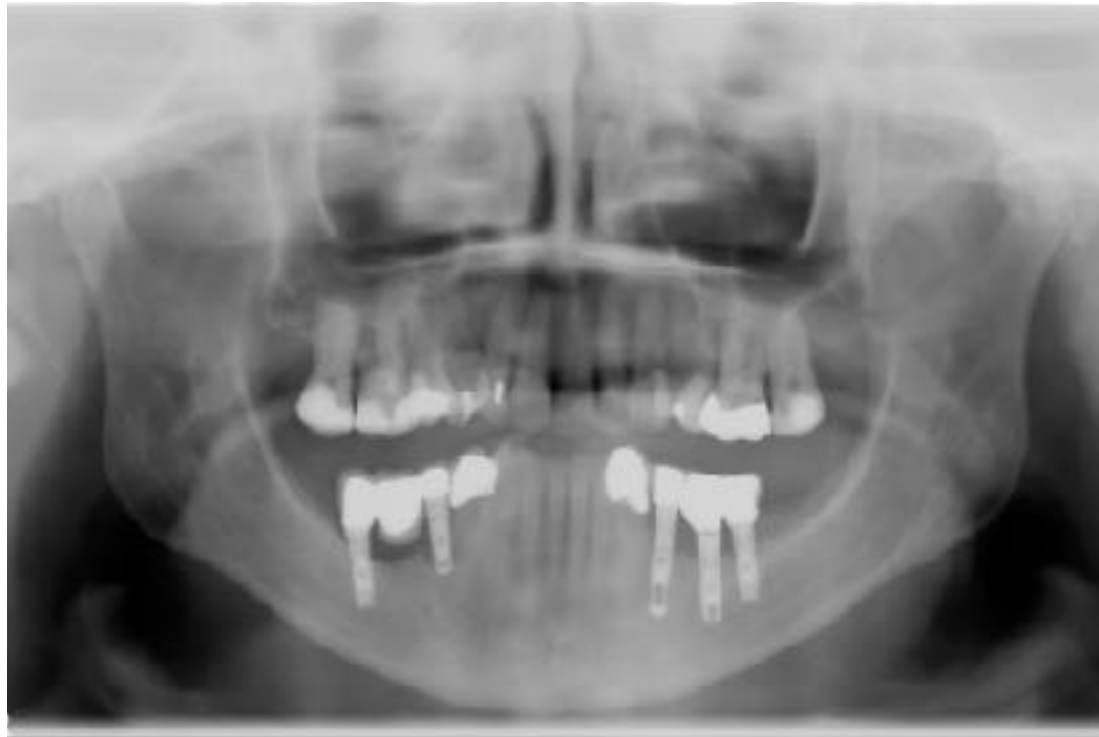

blue<sup>®</sup>m, for the protection of injured periodontal tissue

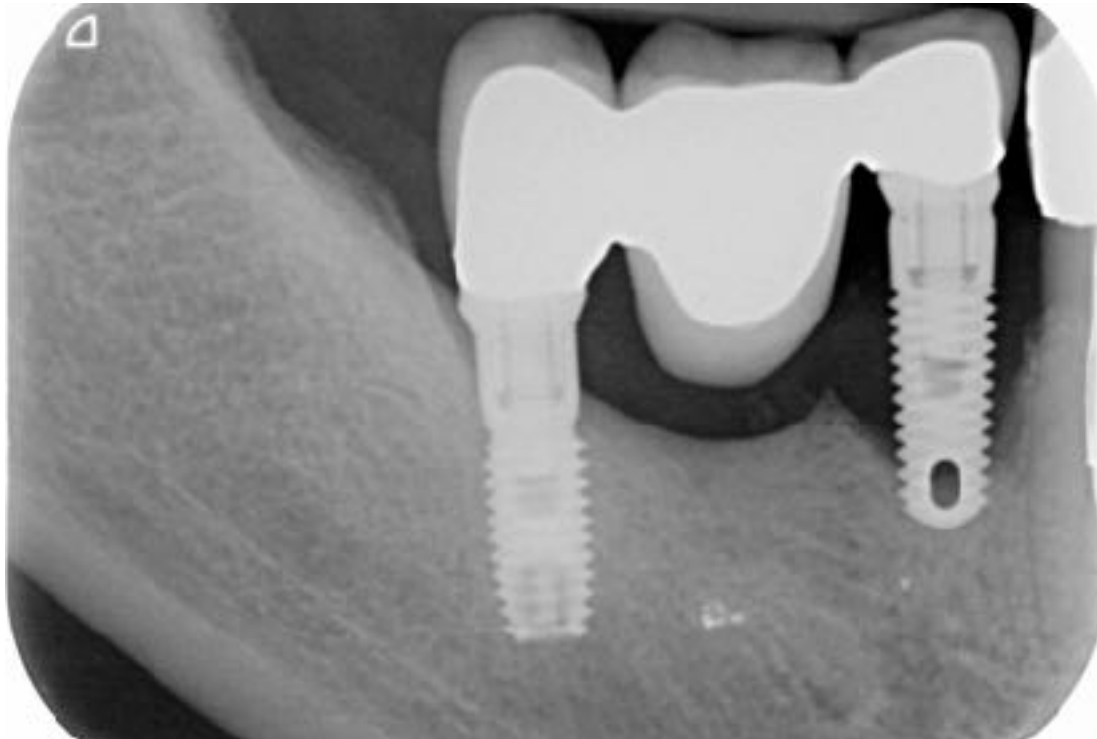
Peri-implantitis of the 4.5 : A 6 year follow -up



X-ray date: 30-06-2014

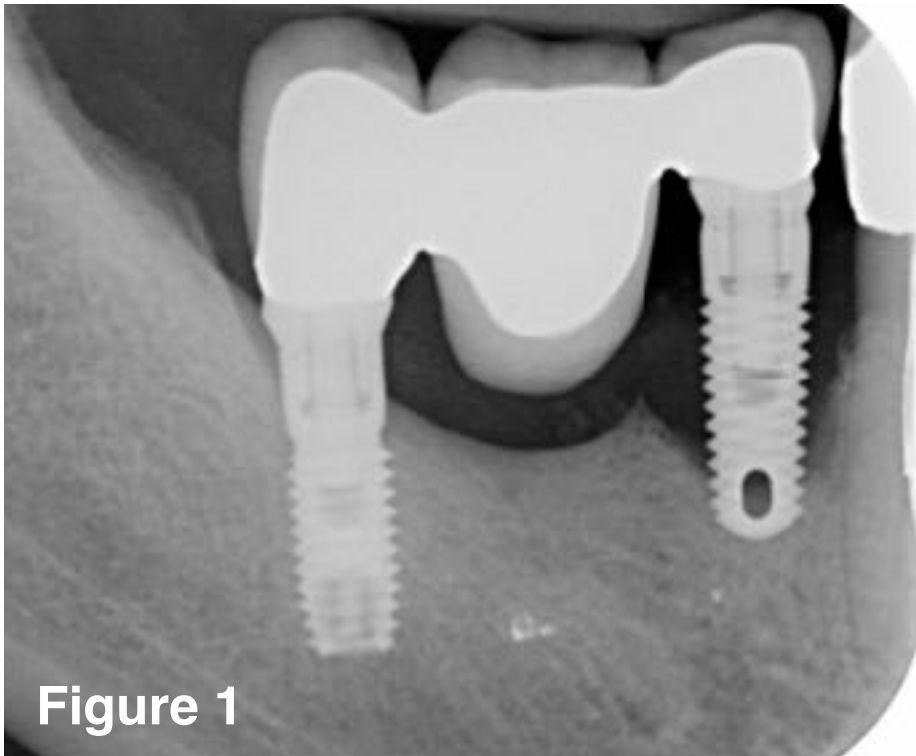
blue<sup>®</sup>m, for the protection of injured periodontal tissue

Peri-implantitis of the 4.5 : A 6 year follow -up



X-ray date: 21-08-2014

blue<sup>®</sup>m, for the protection of injured periodontal tissue

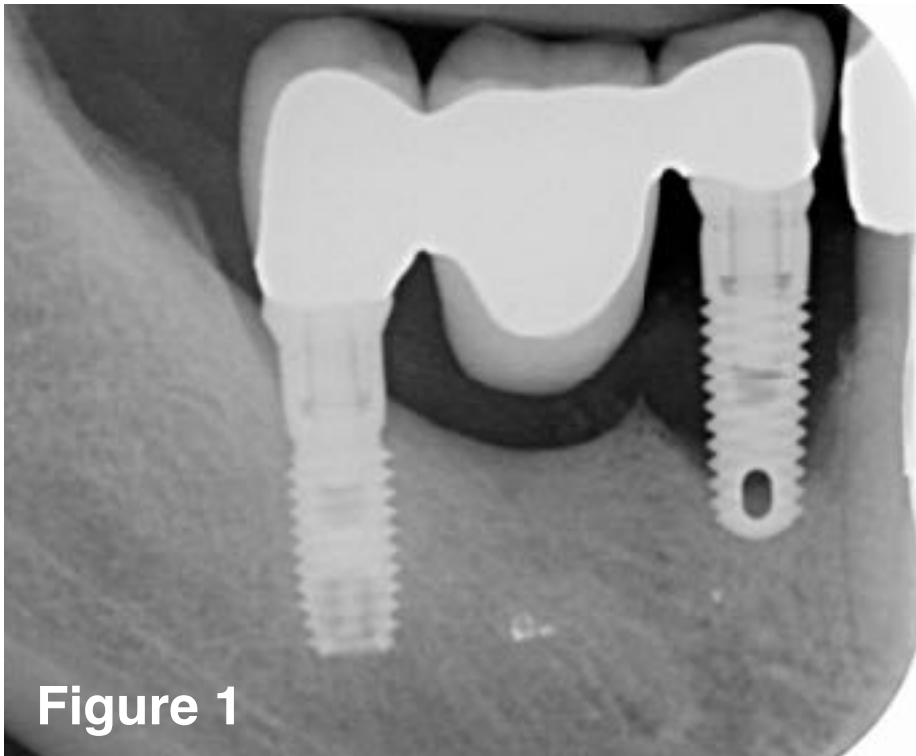


X-ray date: 21-08-2014

## Anamnesis

- Female patient, smoker.
- Patient had implant placement in 2010. Implant was placed in supraposition because of the location of the nervus mentalis and therefore was never completely subgingivally integrated in the bone.
- DNA bacterie test showed a high concentration of PG.
- Therapy: AB metronidazole 500mg 3x1p/d for 7days in combination with flap surgery on the 45.

blue<sup>®</sup>m, for the protection of injured periodontal tissue



X-ray date: 21-08-2014

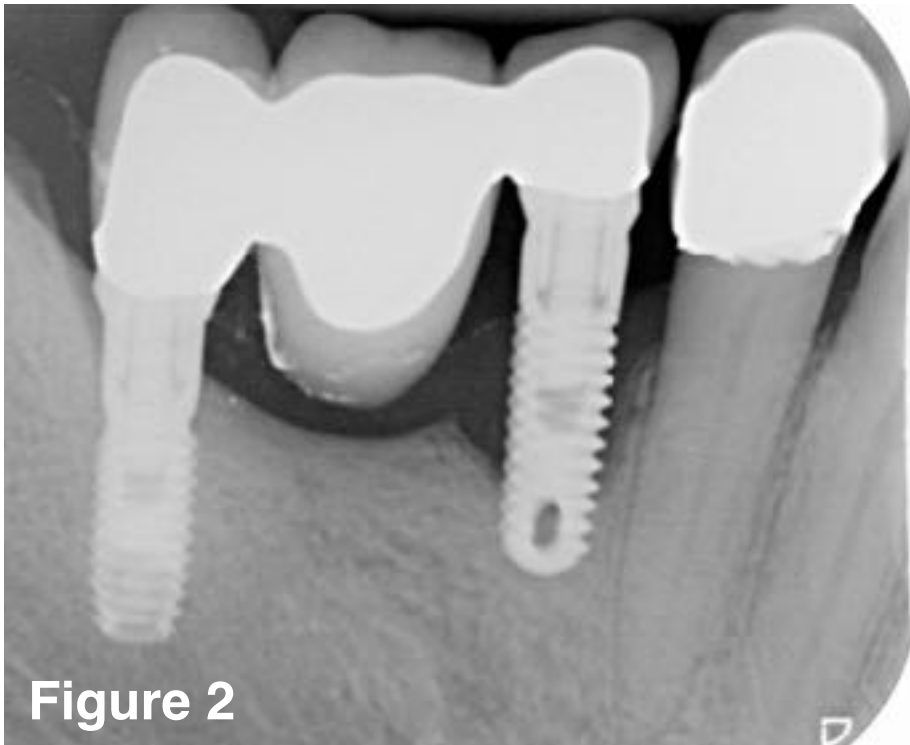
## **Postoperative Control 1 week later**

- Good wound healing
- Removal of the stitches

## **Daily Instructions for the patient**

- Apply blue<sup>®</sup>m oral gel at the 45 and 47 with interdental brushes 2 times daily
- Brush with blue<sup>®</sup>m toothpaste without fluoride

blue<sup>®</sup>m, for the protection of injured periodontal tissue

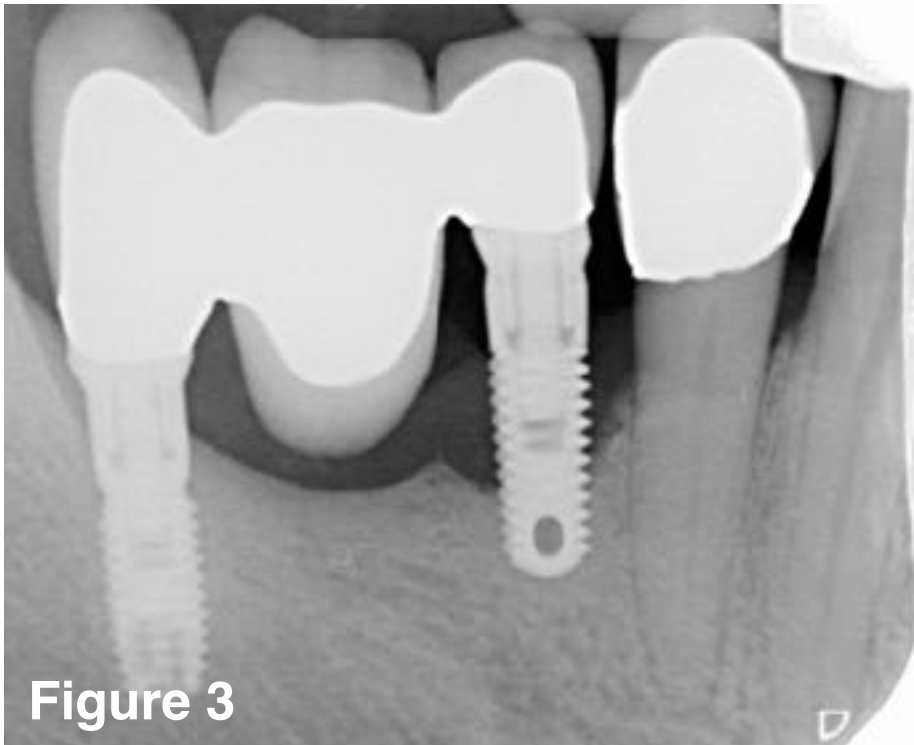


## Postoperative control after 4 months

- Part of the implant is visible supra gingival
- Patients oral hygiene is good
- X-ray shows no further degeneration of bone tissue
- No bleeding on probing

X-ray date: 15-12-2014

blue<sup>®</sup>m, for the protection of injured periodontal tissue



**Figure 3**

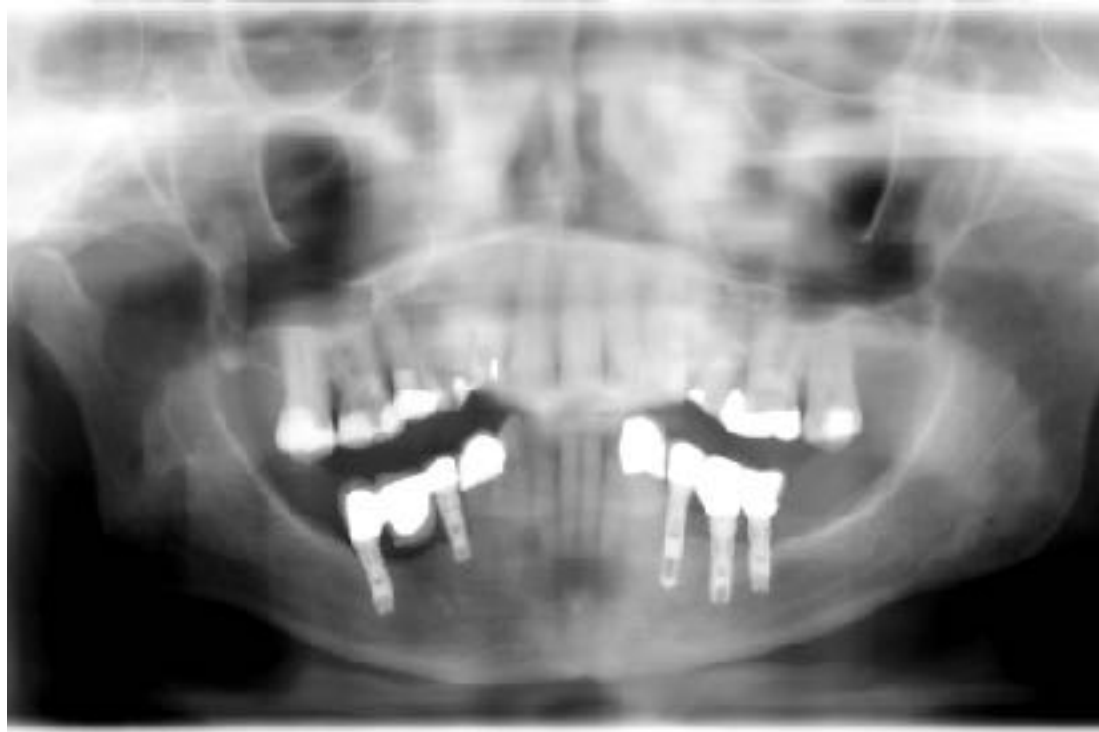X-ray date: 17-06-2015

## **Check up at the dentist almost 1 year later**

- X-ray shows good bone quality
- Patient stopped smoking end of 2015
- Patient still brushes with blue<sup>®</sup>m fluoride free toothpaste

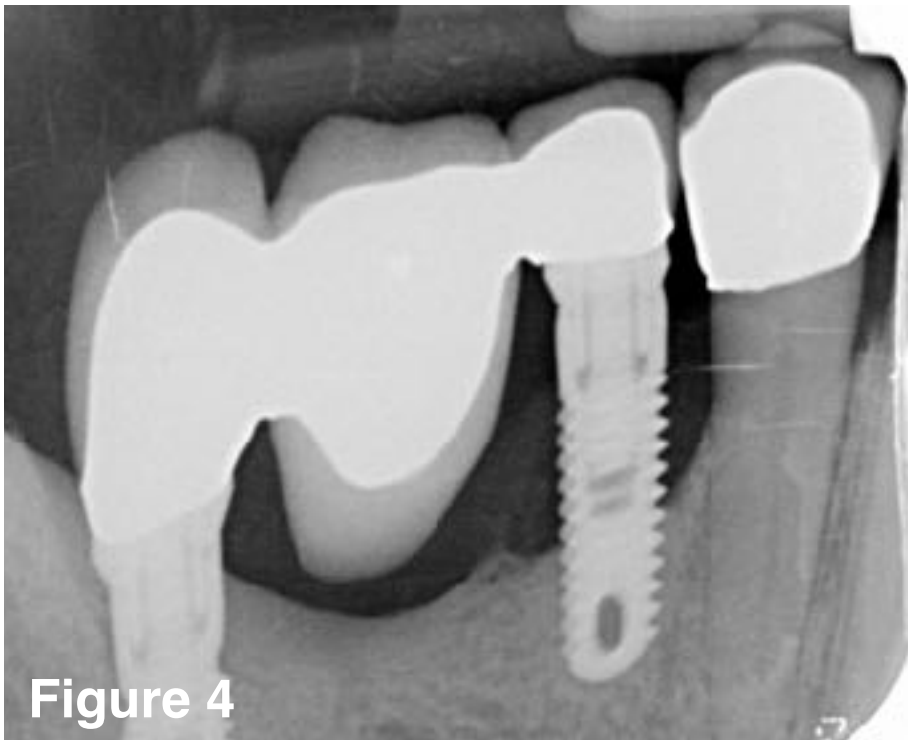
blue<sup>®</sup>m, for the protection of injured periodontal tissue

Peri-implantitis of the 4.5 : A 6 year follow -up



X-ray date: 19-12-2016

blue<sup>®</sup>m, for the protection of injured periodontal tissue



**Figure 4**

X-ray date: 27-06-2017

## **Check up at the dentist 2 years later**

- X-ray bone quality looks even better
- 45 shows bleeding on probing because the implants screw is difficult to clean
- Patient keeps on brushing with blue<sup>®</sup>m fluoride free toothpaste and will start to apply blue<sup>®</sup>m oral gel with interdental brushes at the 45 again



blue<sup>®</sup>m, for the protection of injured periodontal tissue

The implant 45 shown on the X-Ray of 21-08-2014 (Figure 1) and on the X-Ray of 27-06-2017 (Figure 4)

