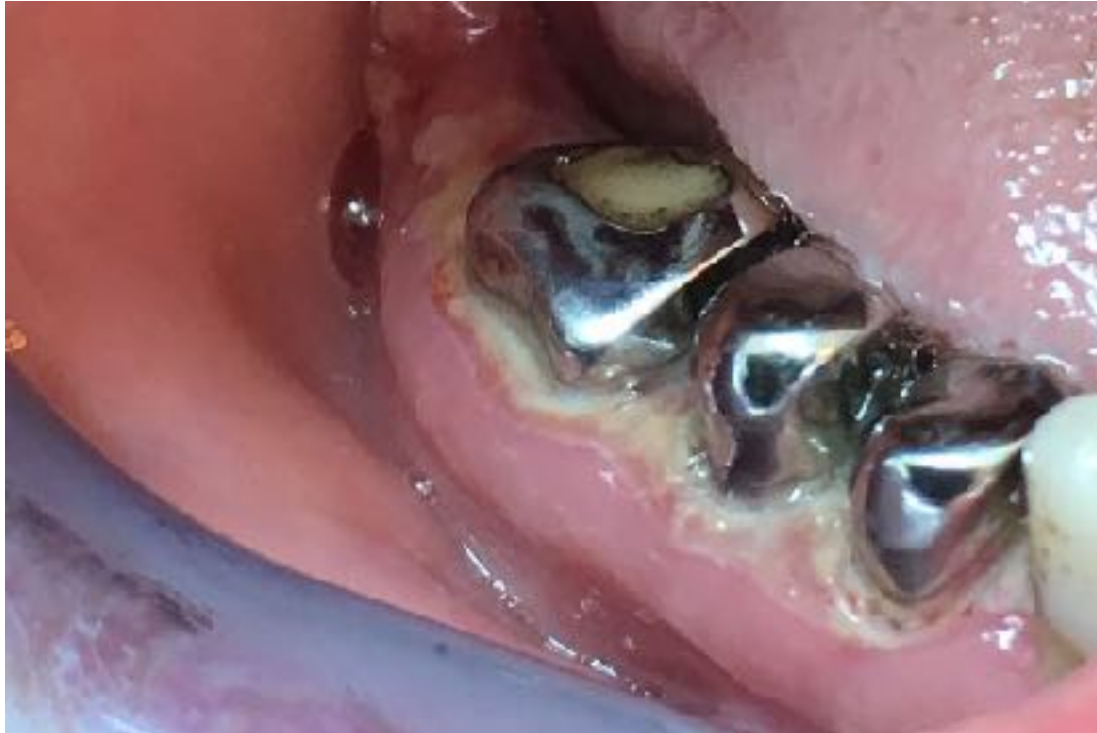

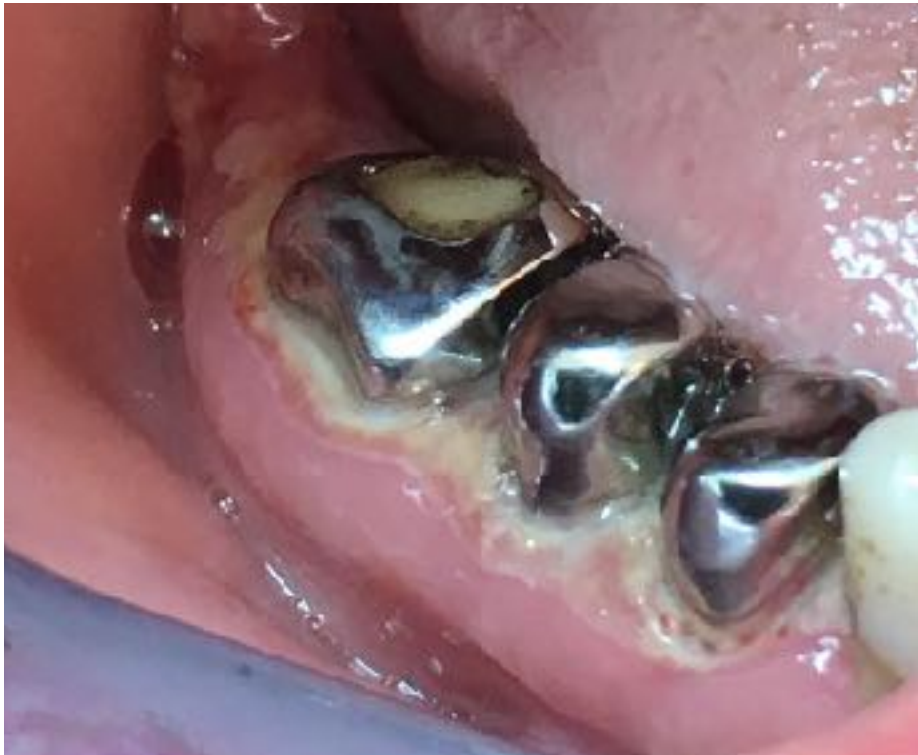blue[®]m, for the protection of injured periodontal tissue

Inflammation of the 4.4 -4.5 -4.6



01-02-2017

blue[®]m, for the protection of injured periodontal tissue

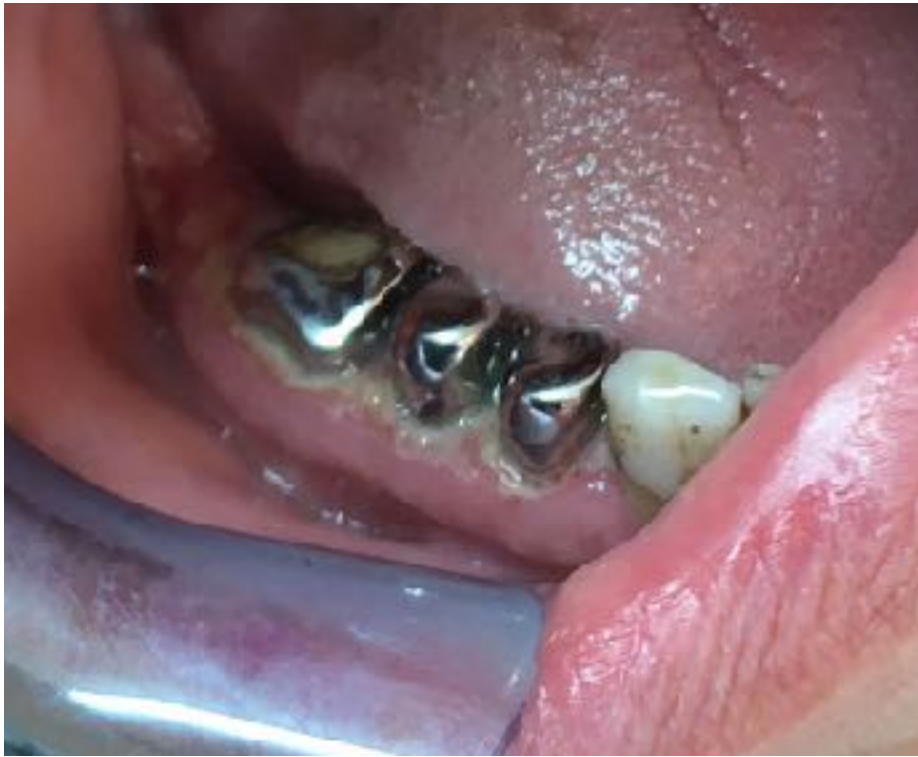

01-02-2017

Anamnesese

- Female
- 60+ years
- Nonsmoker
- Kidney disease diagnosed
- Good oral hygiene
- DNA bacterie test showed a high concentration of PG.
- Tested negative for Oral Lichen Planus and Candida Albicans

blue[®]m, for the protection of injured periodontal tissue



Start using blue[®]m 12-05-2017

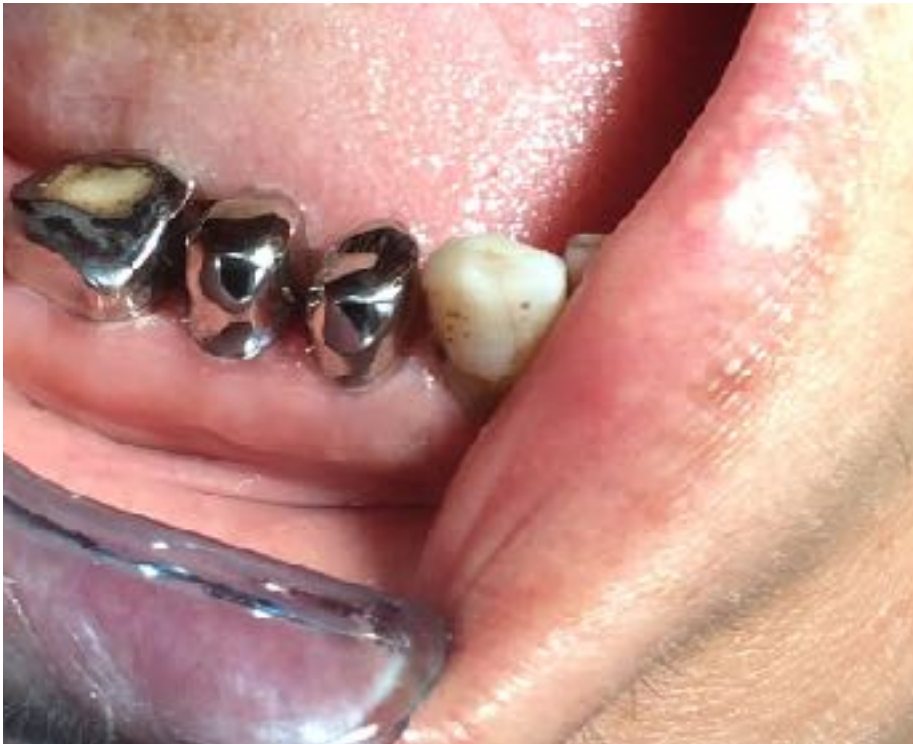Previous therapy

- Patient had multiple treatment with CHX-gel, Bio-C and Cupral without result
- Therapy: AB metronidazole 500mg 3x1p/d for 7days without result

Instructions for the patient 12-05-2017

- Brush with blue[®]m Toothpaste 2-3 times daily
- Apply blue[®]m Oral gel multiple times daily

blue[®]m, for the protection of injured periodontal tissue

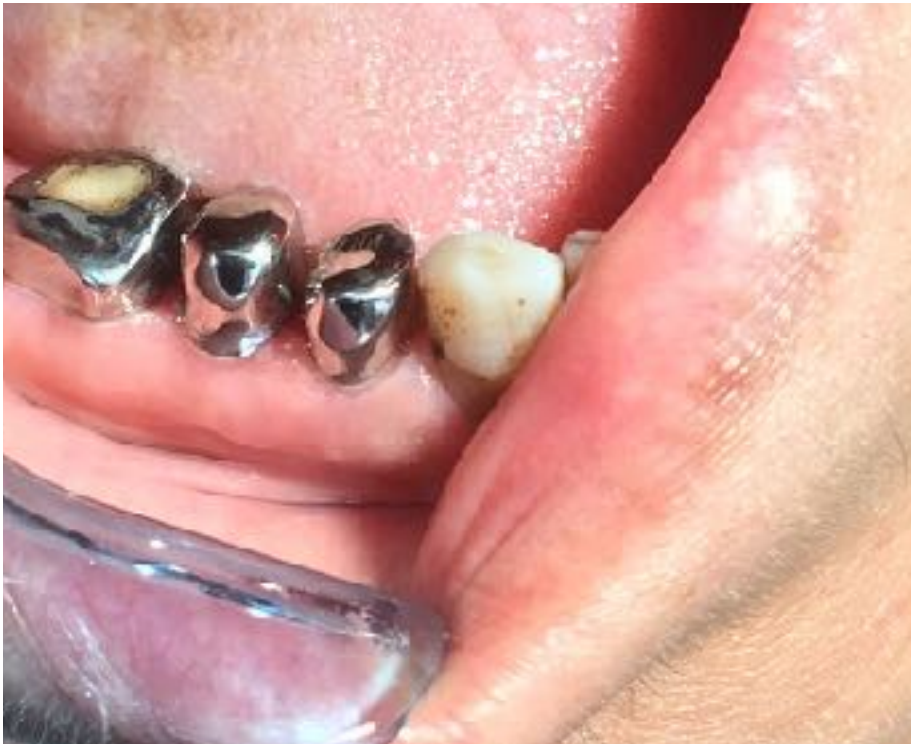

Control after 2 weeks

- Immediate improvement after start using blue[®]m Toothpaste and Oral gel

26-05-2017

blue[®]m, for the protection of injured periodontal tissue

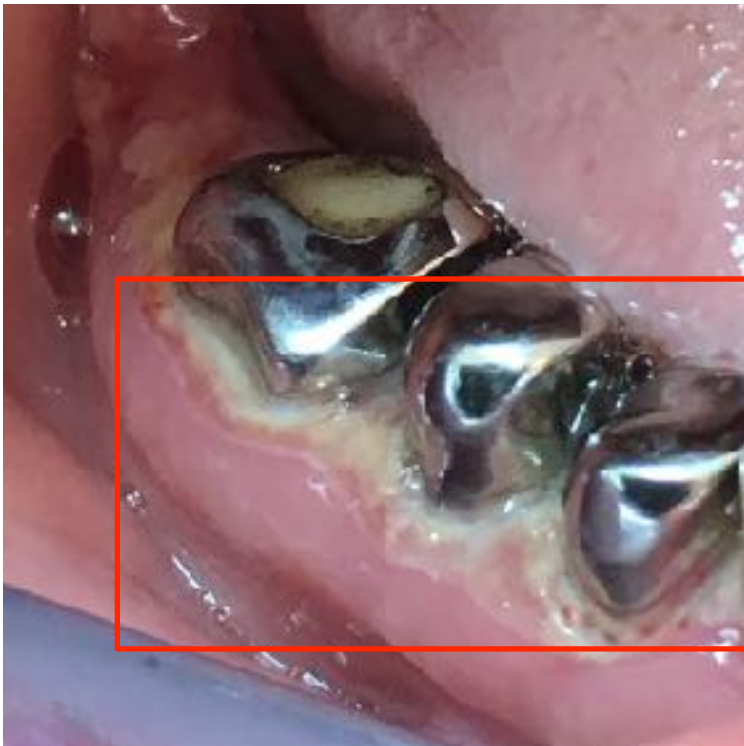


**Check up at the dentist
every 6 months**

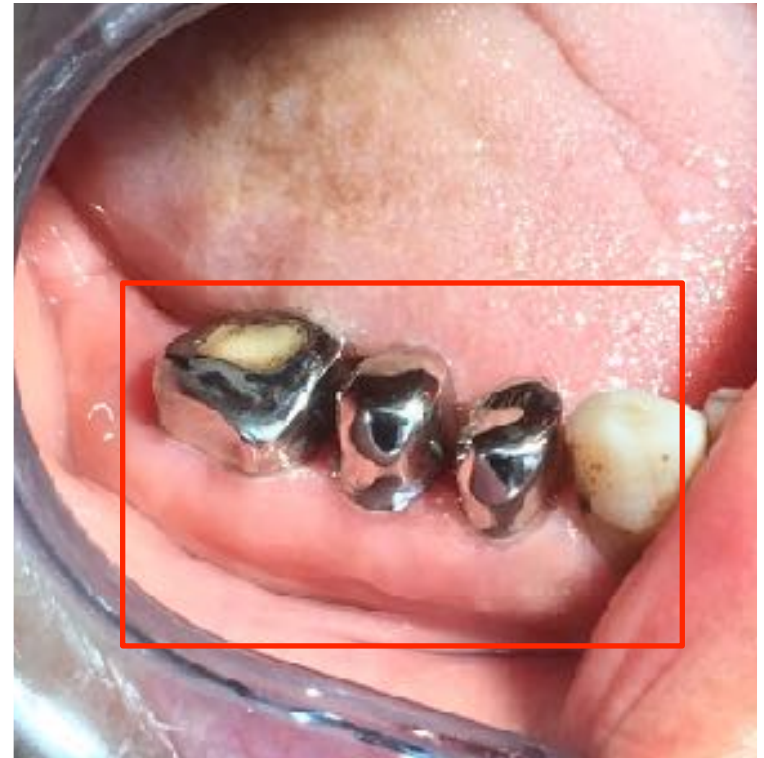- Gingival area 4.4-4.7 shows no more signs of inflammation or irritation
- Patient still brushes with blue[®]m Toothpaste with fluoride
- Patient rinses with blue[®]m Mouthwash 2 times daily

blue[®]m, for the protection of injured periodontal tissue

Inflammation of the 4.4 -4.5 -4.6



Before using blue[®]m



After using blue[®]m