

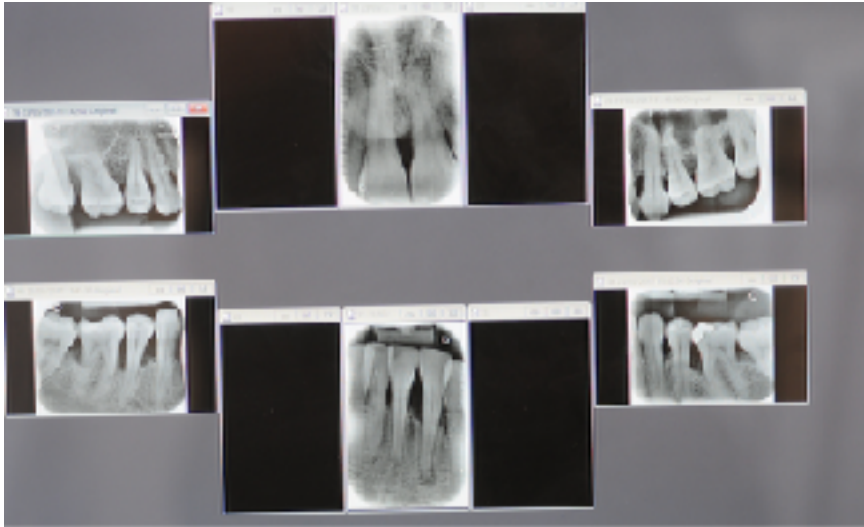
Periodontitis: Initial therapy supported with blue[®]m oral gel. A follow-up



Drs.Amit Patel BDS MSc MClintDent RCSed MRD
RCSEng

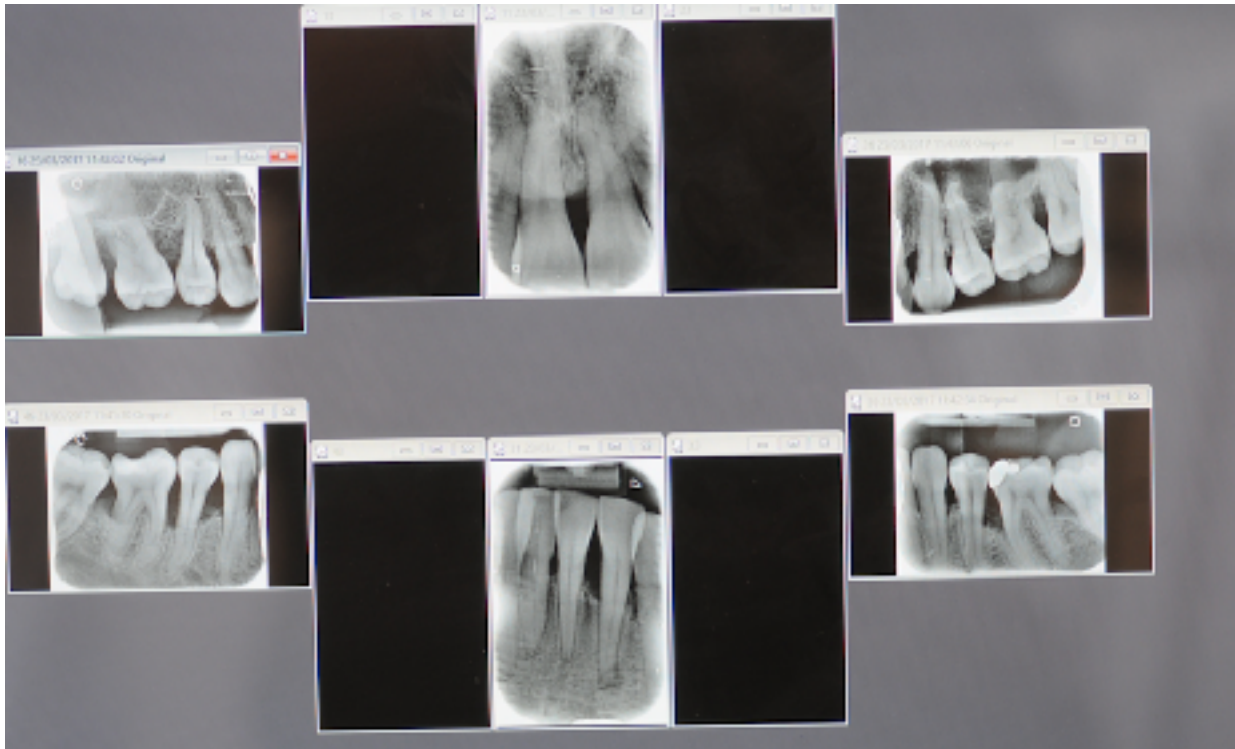
- Studied Dentistry at the University of Liverpool
- Graduated 4 year training program in Periodontics at Guy's, King's & St Thomas Dental Institute
- Associate Specialist in Periodontics at the Birmingham Dental Schools
- Honorary Clinical lecturer at the University and teaches master students
- Lecturing to dental practitioners both in the UK and internationally

Periodontitis: Initial therapy supported with blue[®]m oral gel. A follow-up

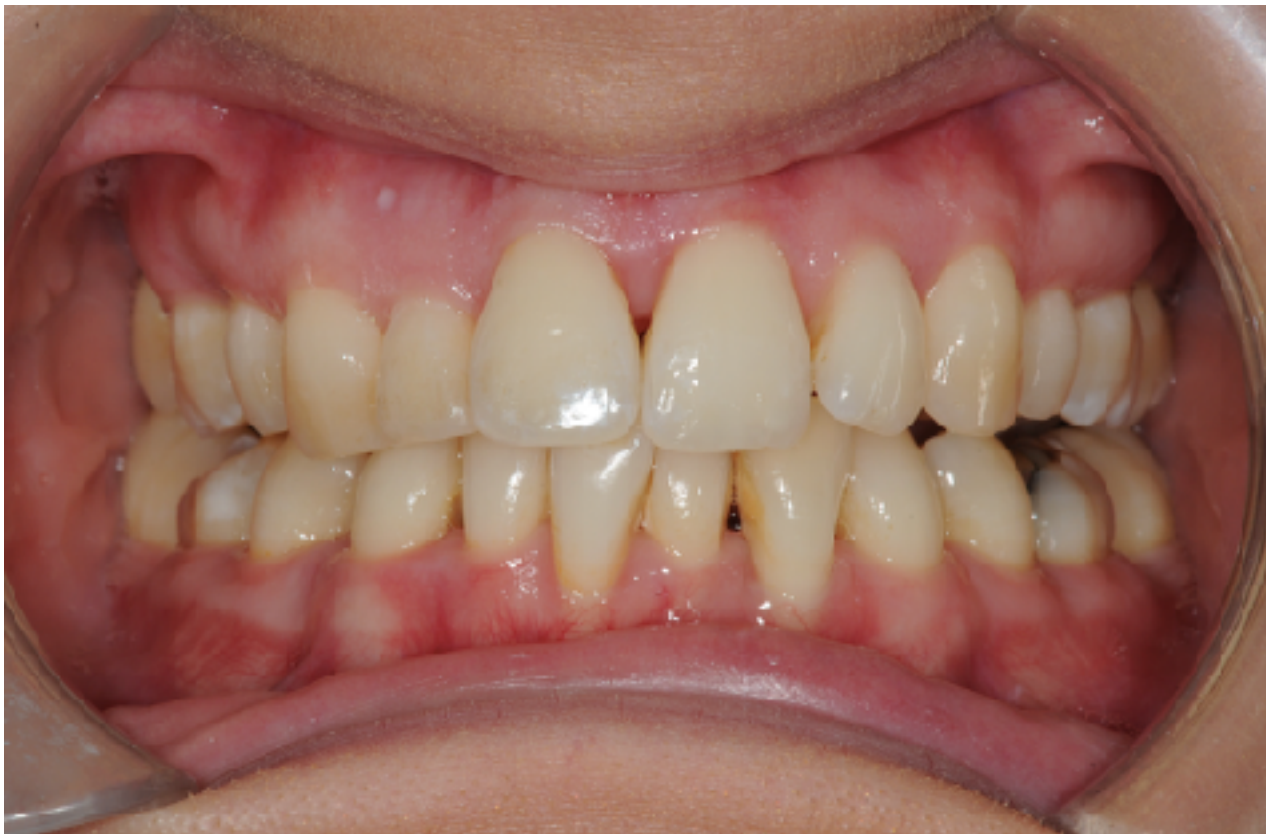

- Woman 28 years old
- Periodontitis with pockets of 7/8 mm in the (pre)molar area of the upper jaw
- Pockets of 8/9 mm in the lower jaw
- Multiple furcations grade I/II

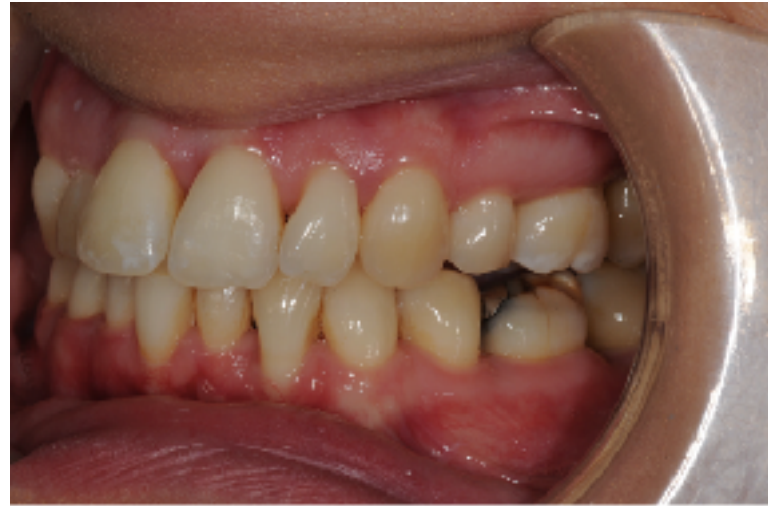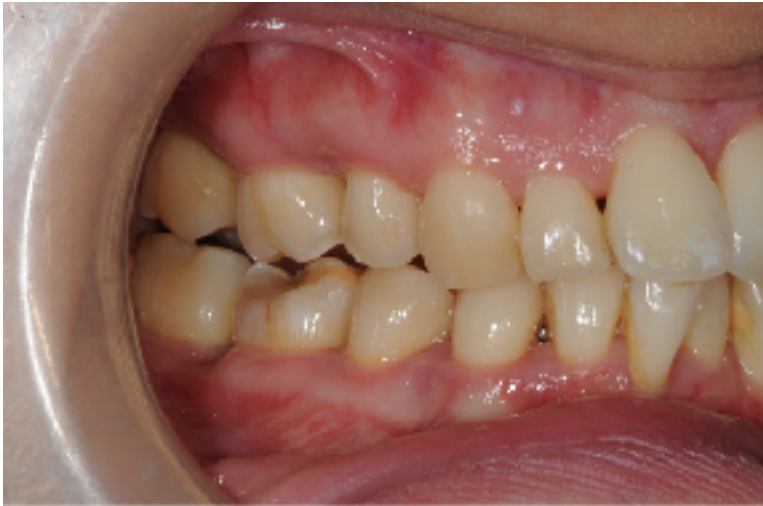X-Ray before therapy 2017-06-12

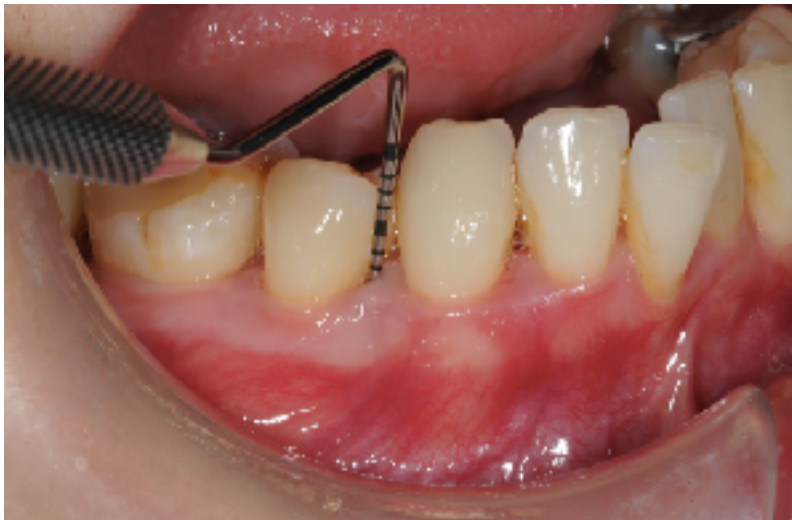
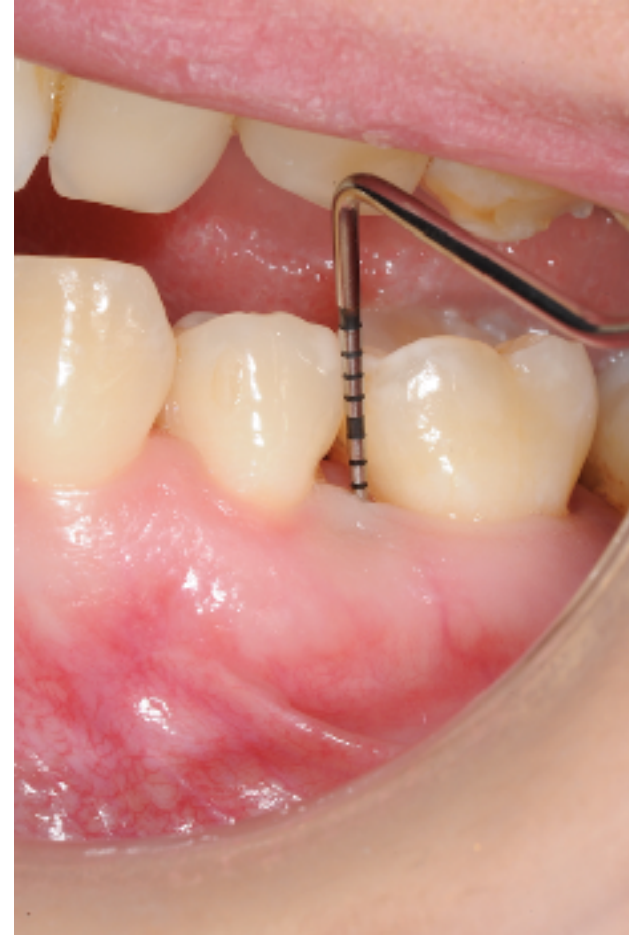
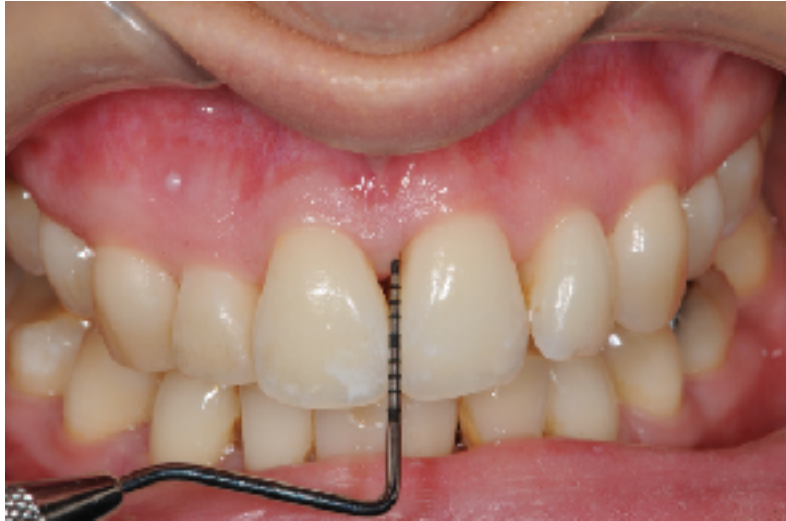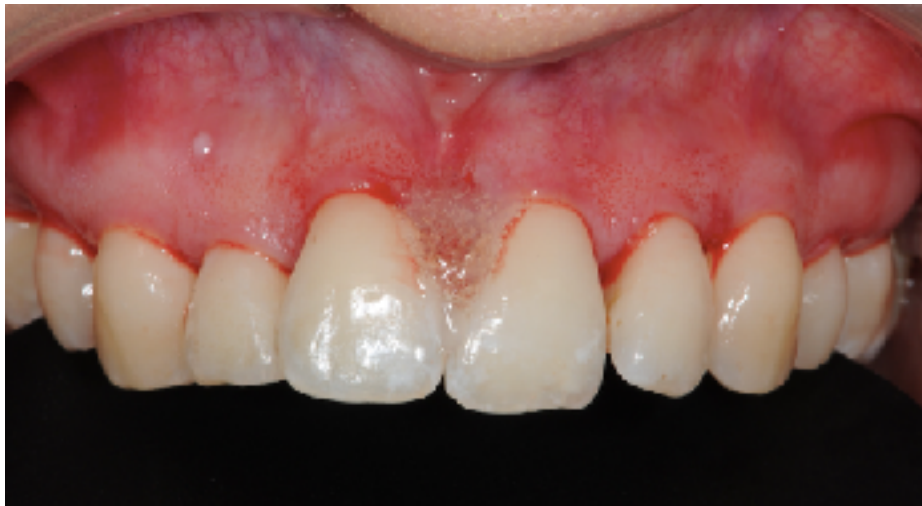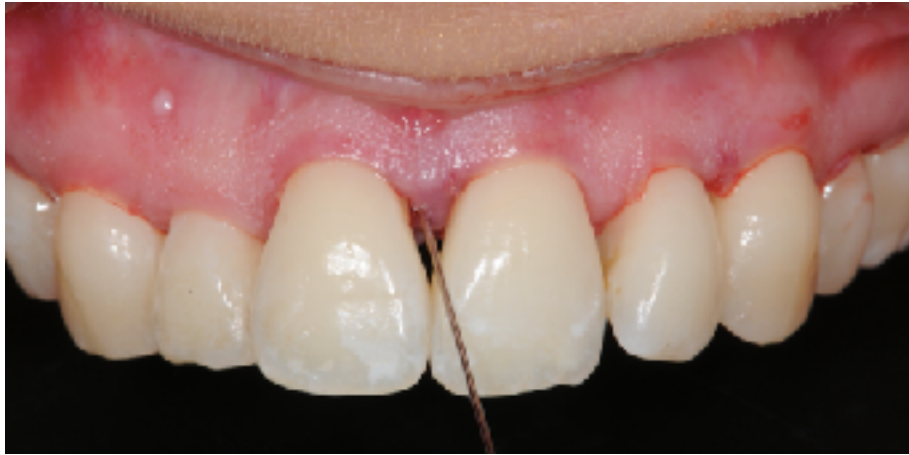Notice the large amount of (angular) bone loss at this young age and peri-apical inflammation



- Swollen gums,
- Pockets up to 9 mm
- Multiple furcations
- Bleeding after probing

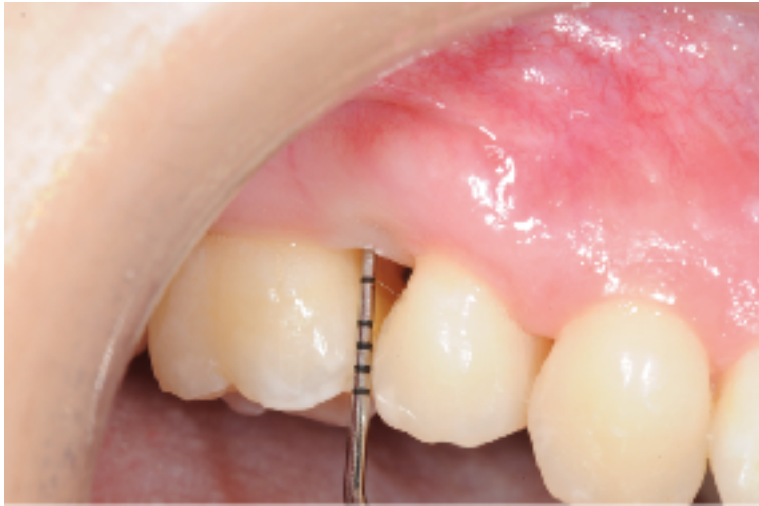





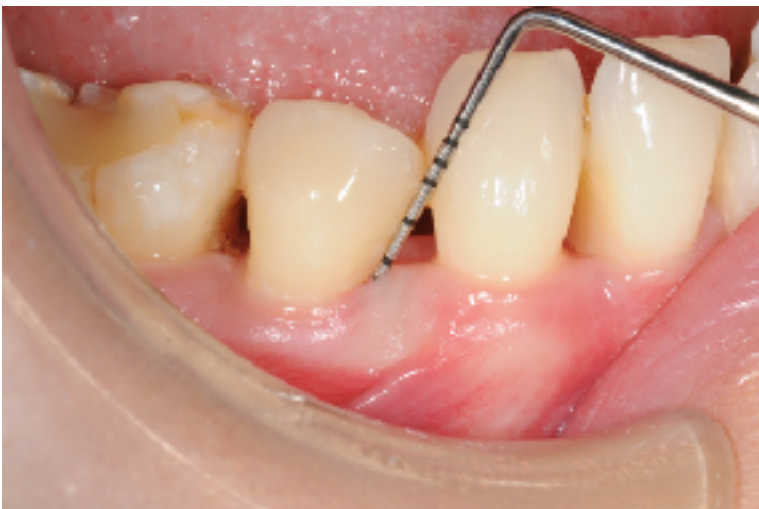2017-06-22

- Scaling and rootplaning
- Laser therapy
- Oral hygiene reinforcement
- blue[®]m oral gel

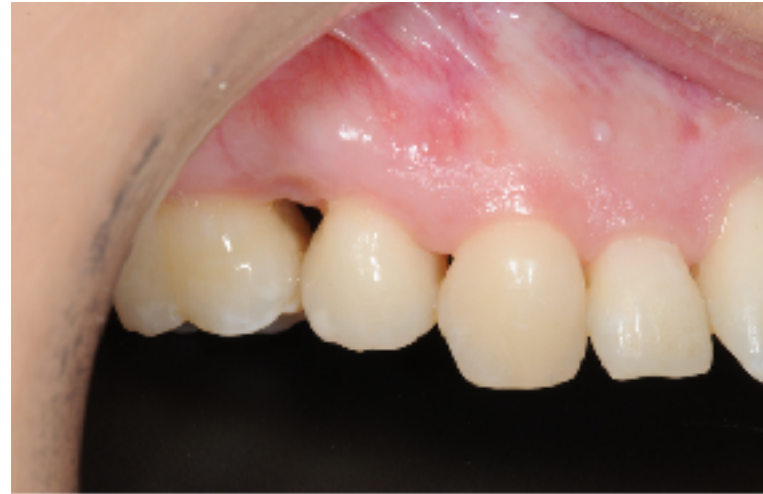
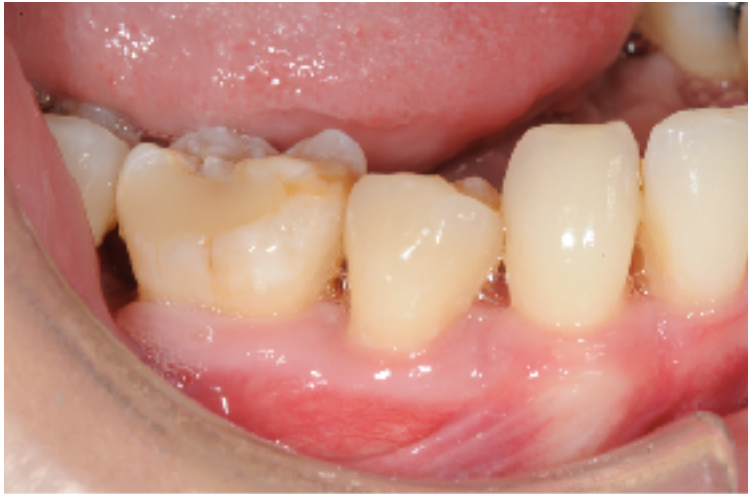
2017-08-07

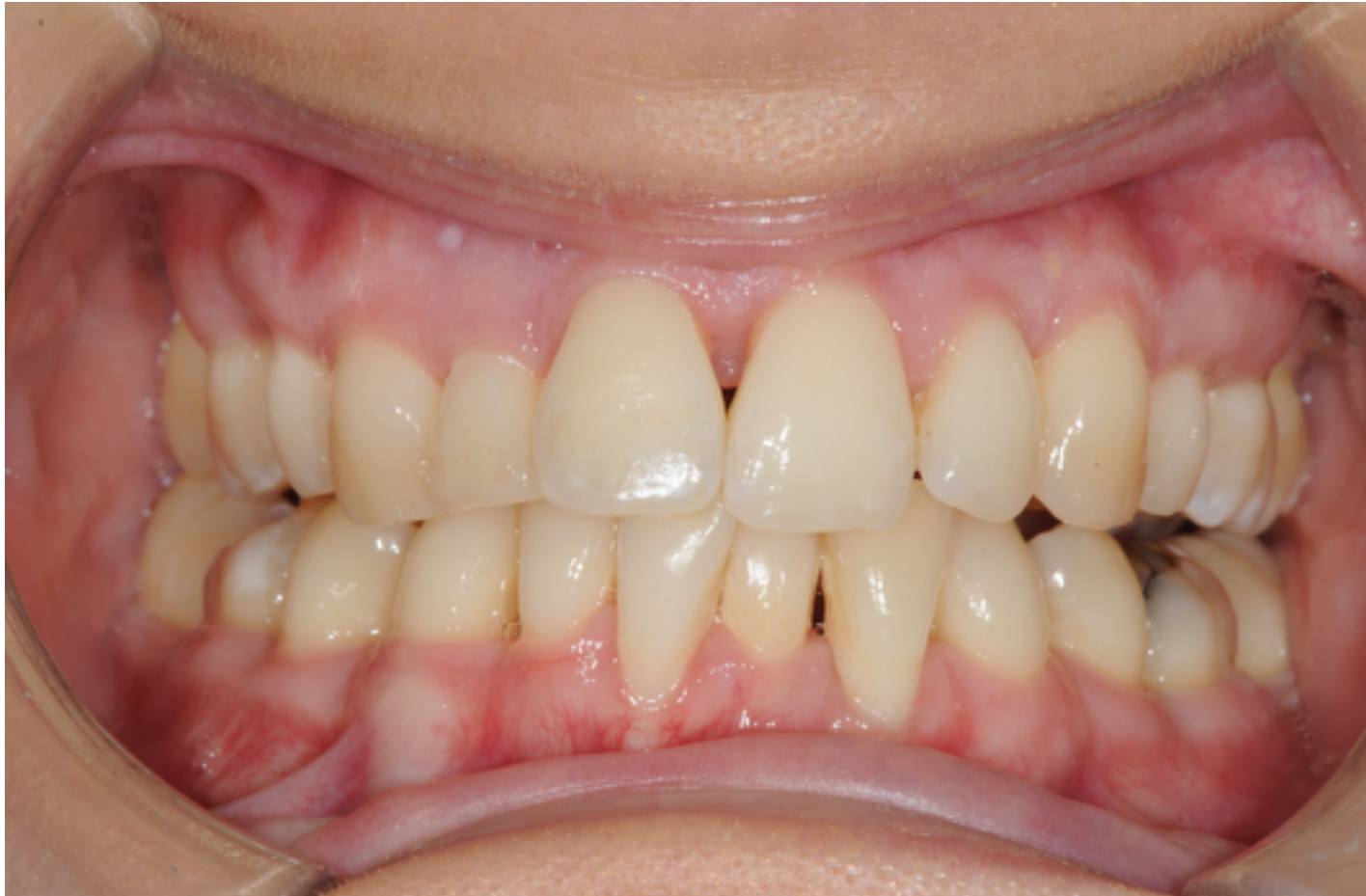Periodontal
evaluation after 6
weeks blue[®]m oral
gel



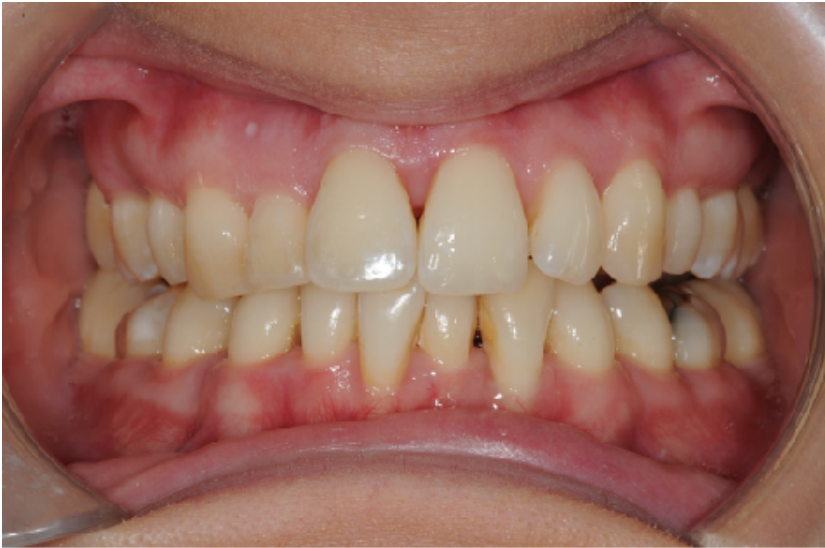Periodontal evaluation after 6 weeks blue[®]m oral gel



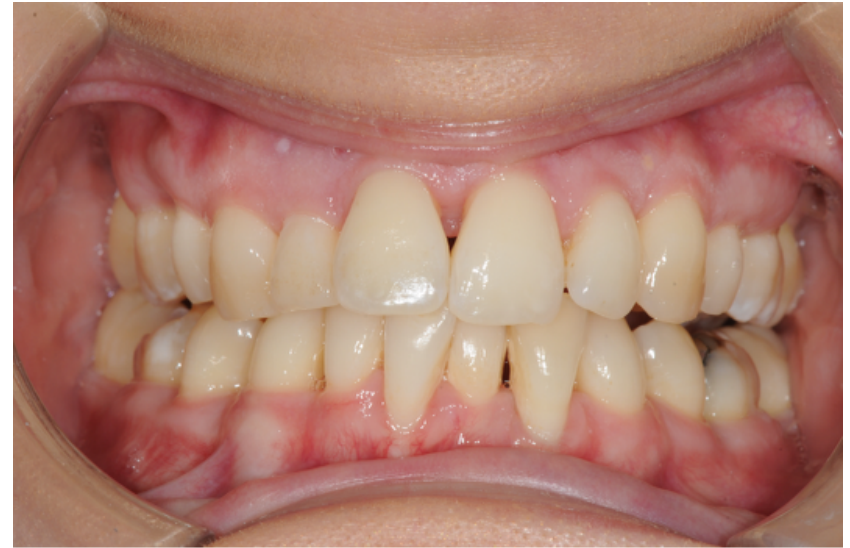Periodontal evaluation after 6 weeks blue[®]m oral gel



Periodontal evaluation after rootplaning, laser treatment and 6 weeks blue[®]m oral gel



Before initial therapy



After initial therapy