

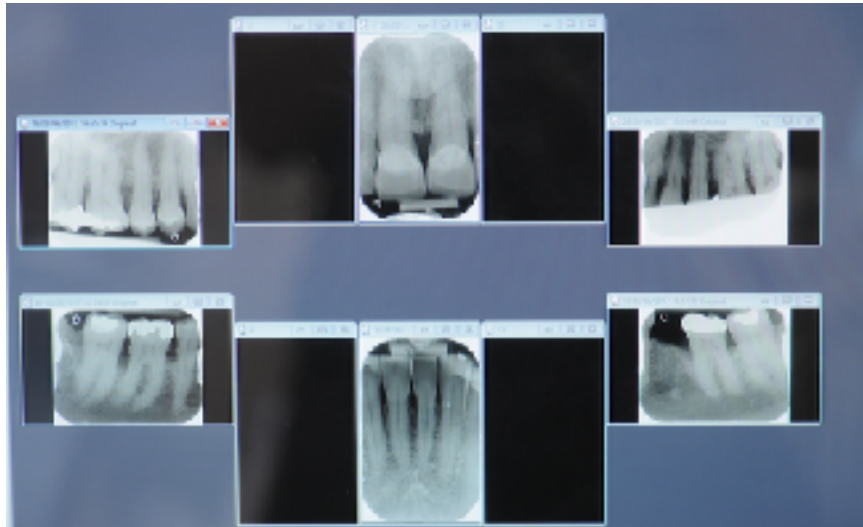
Periodontitis: Initial therapy supported with blue[®]m oral gel. A follow-up



Drs.Amit Patel BDS MSc MClintDent RCSed MRD
RCSEng

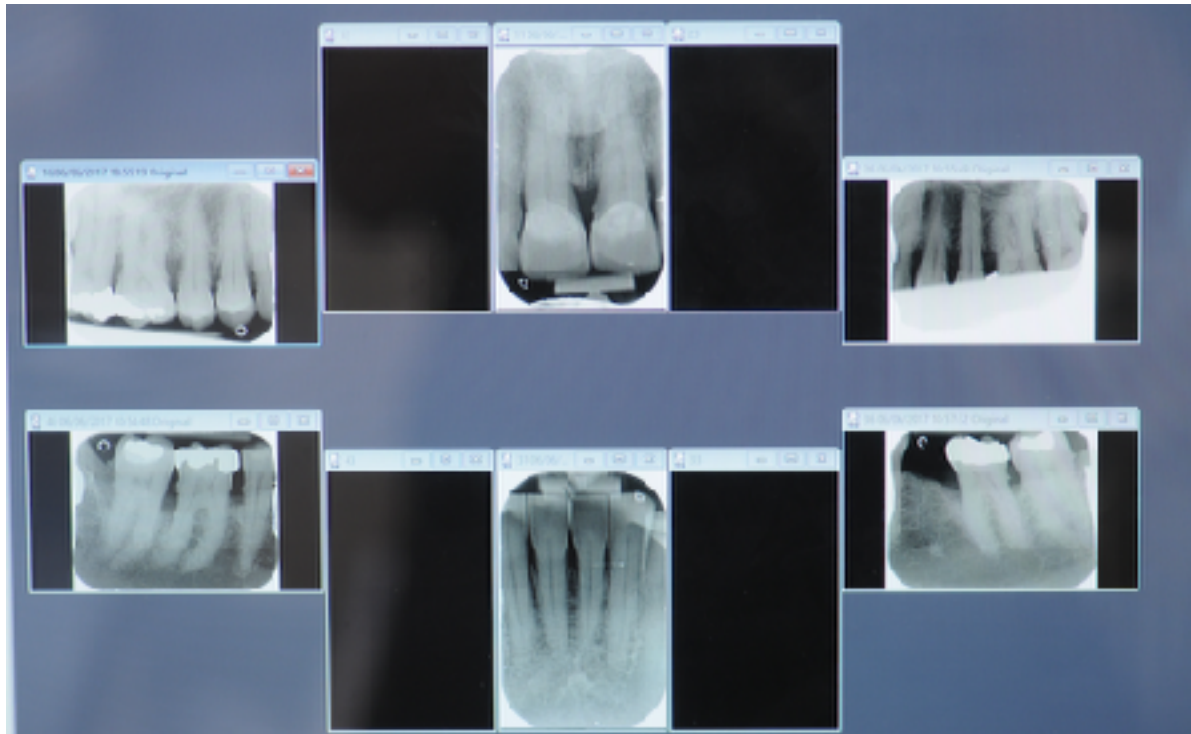
- Studied Dentistry at the University of Liverpool
- Graduated 4 year training program in Periodontics at Guy's, King's & St Thomas Dental Institute
- Associate Specialist in Periodontics at the Birmingham Dental Schools
- Honorary Clinical lecturer at the University and teaches master students
- Lecturing to dental practitioners both in the UK and internationally

Periodontitis: Initial therapy supported with blue[®]m oral gel. A follow-up



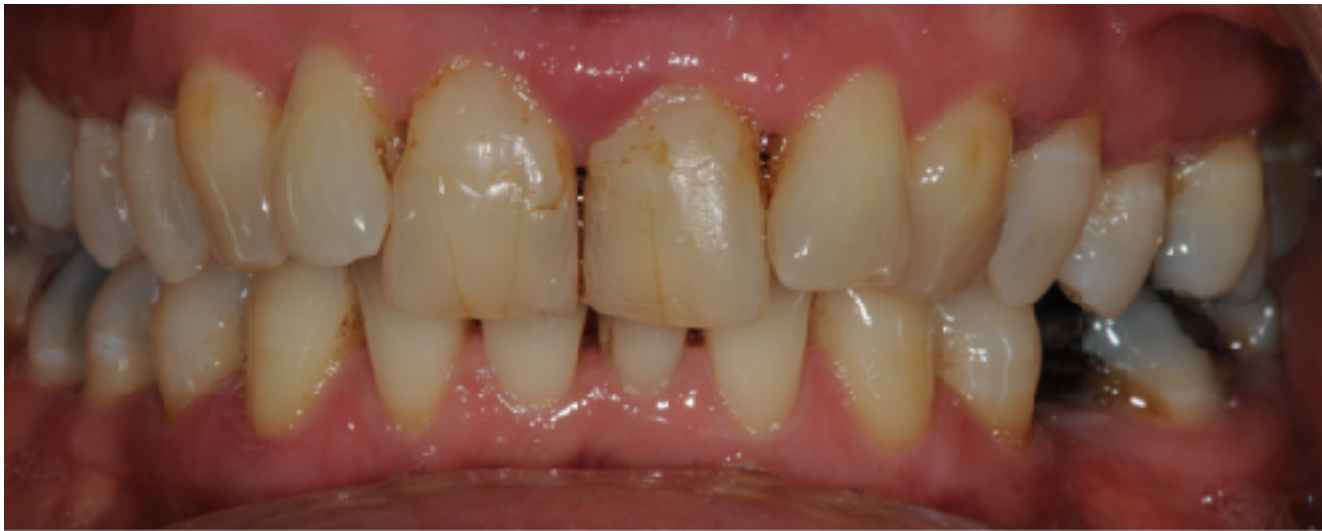- Woman 58 years old
- Periodontitis with pockets of 6/7 mm in the (pre)molar area of the upper jaw
- Pockets of 7/8 mm in the lower jaw
- Multiple furcations in the 1th, 2nd and the 4th quadrant

X-Ray before therapy 2017-06-06

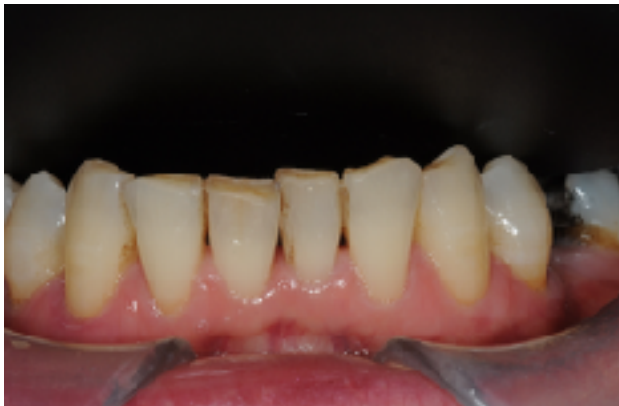
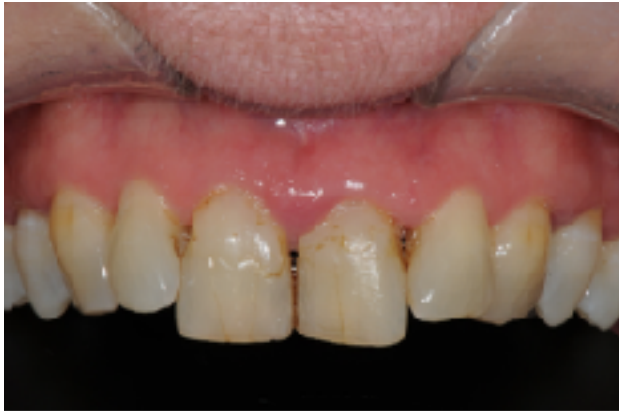
Notice the large amounts of sub-gingival calculus and bone loss

Intake 2017-06-06

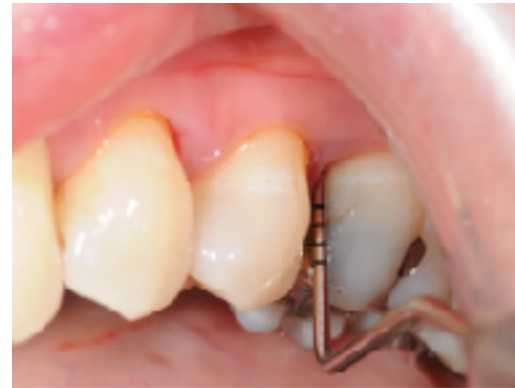
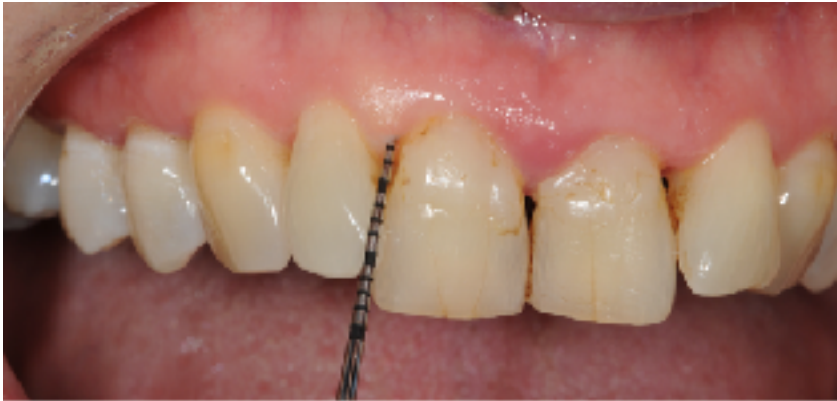
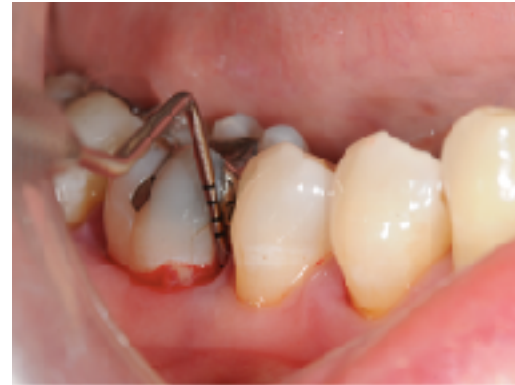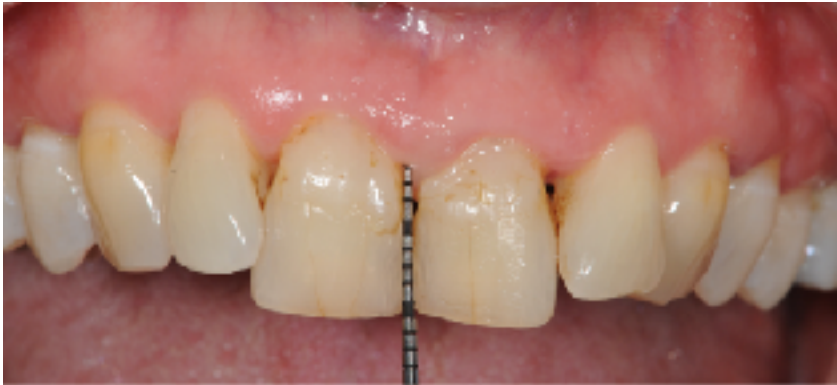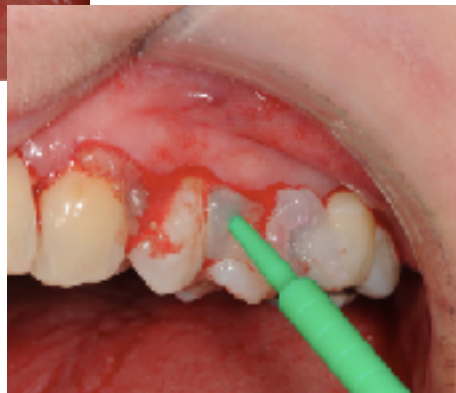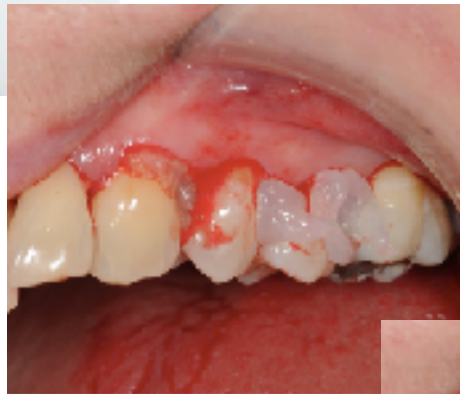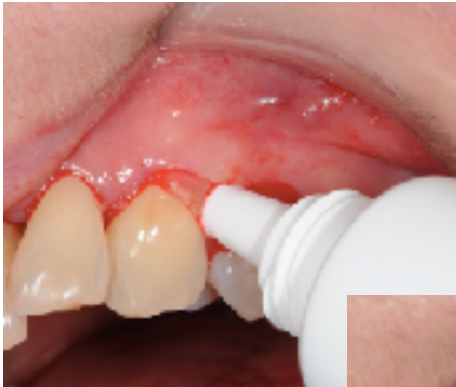- Swollen gums,
- Pockets up to 8 mm
- Multiple furcations
- Bleeding after probing



Intake 2017-06-06

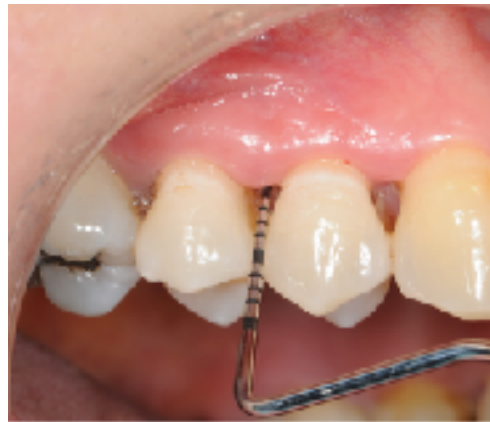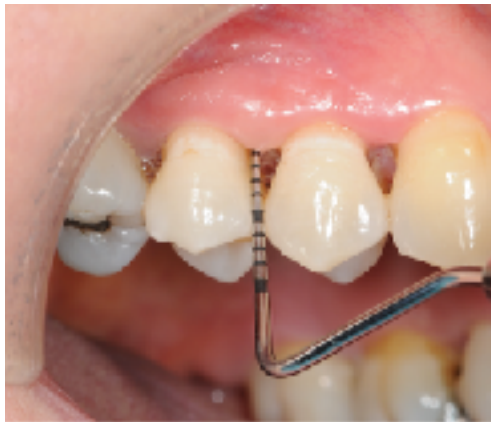- Swollen gums,
- Pockets up to 8 mm
- Multiple furcations
- Bleeding after probing





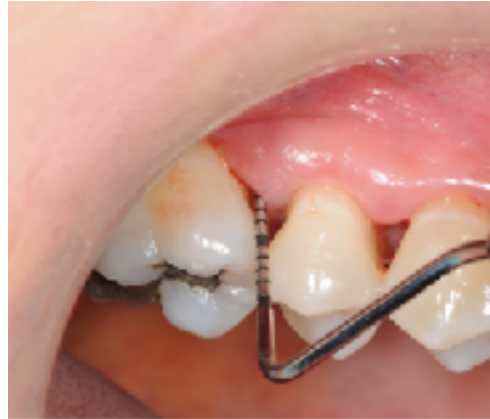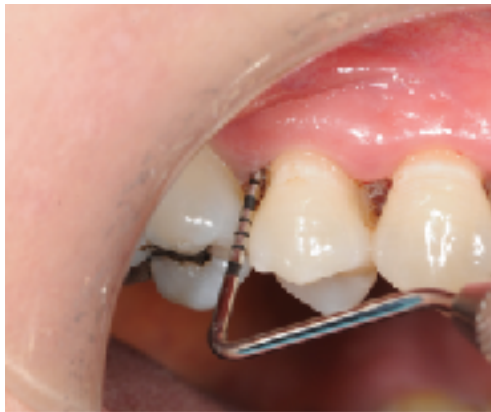2017-07-24

- Scaling and rootplaning
- Laser therapy
- Oral hygiene reinforcement
- blue[®]m oral gel



2017-08-03

Periodontal
evaluation after
1,5 week blue[®]m
oral gel



Periodontal evaluation after 1,5 week blue[®]m oral gel

