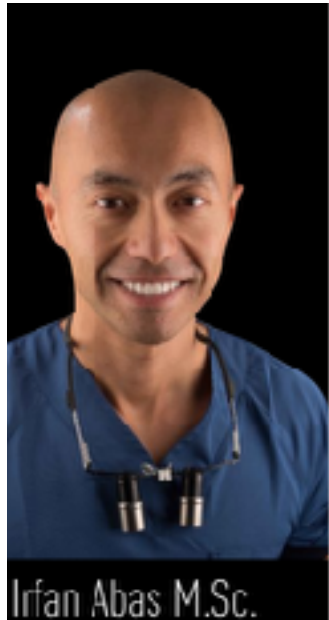

blue<sup>®</sup>m, for the protection of injured periodontal tissue

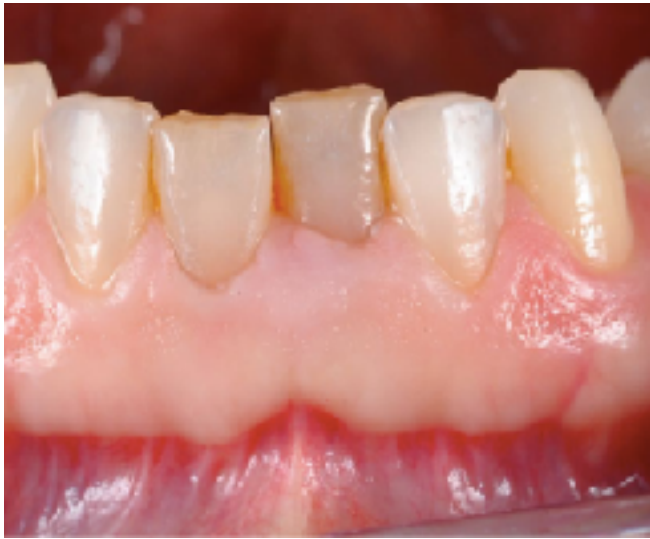

Drs. Irfan Abas

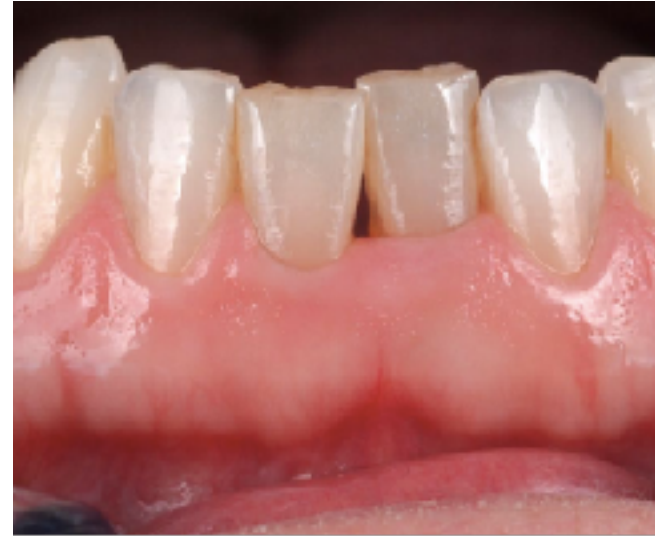- 2002-2008 Studied Dentistry at the Amsterdam University
- 2010-2014 Studied Reconstructive Dentistry at the Nijmegen University
- Is since then acknowledged Restorative Dentist by the NVvRT

blue<sup>®</sup>m, for the protection of injured periodontal tissue

Chronic periodontitis 31-41: Initial therapy supported with blue<sup>®</sup>m oral gel. A 6 week follow-up

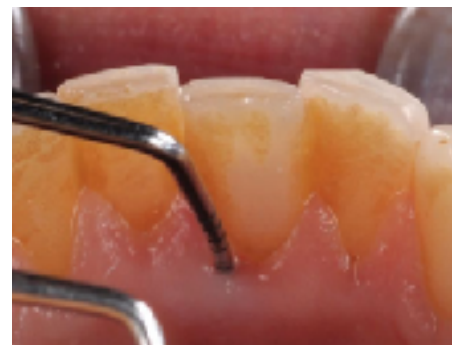
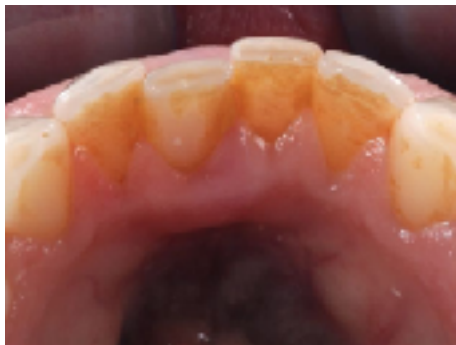
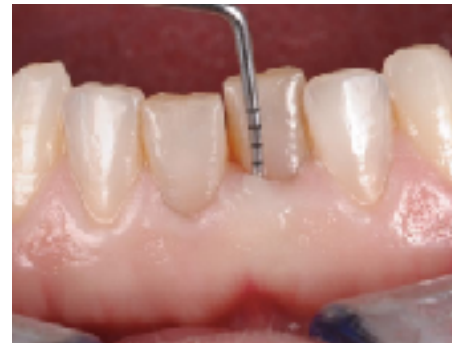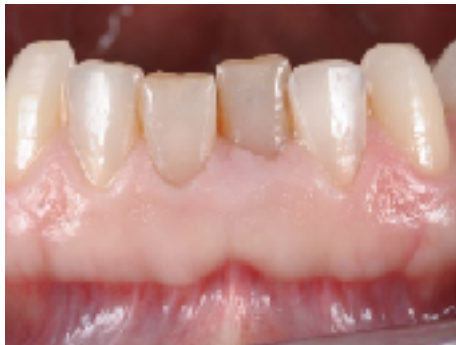Before therapy



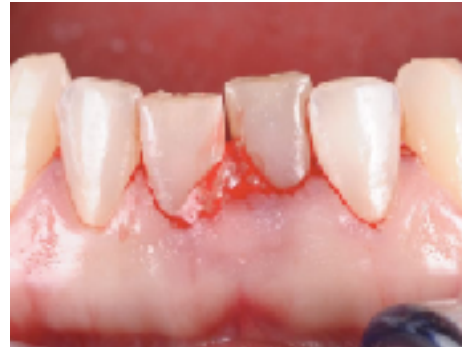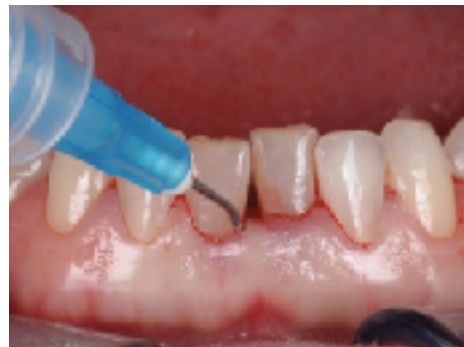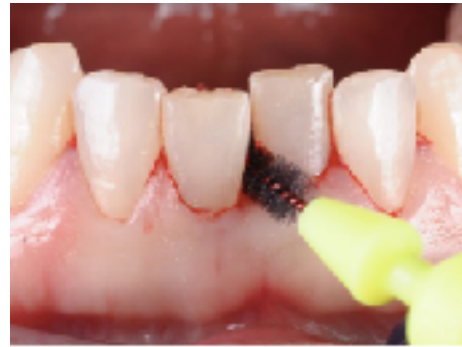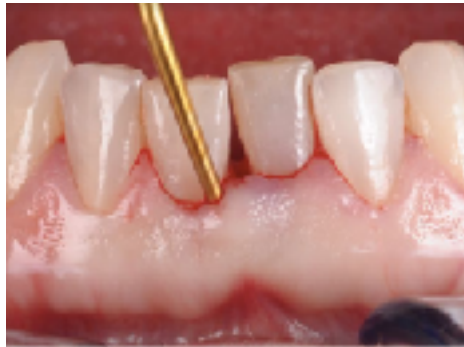After 6 weeks

blue<sup>®</sup>m, for the protection of injured periodontal tissue



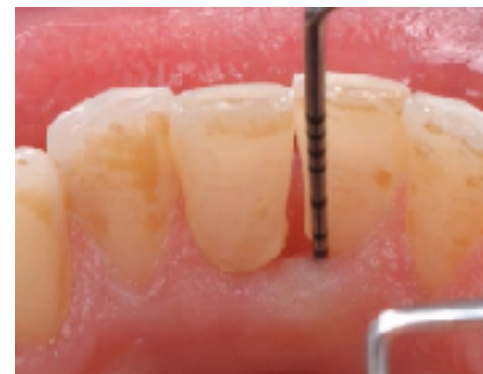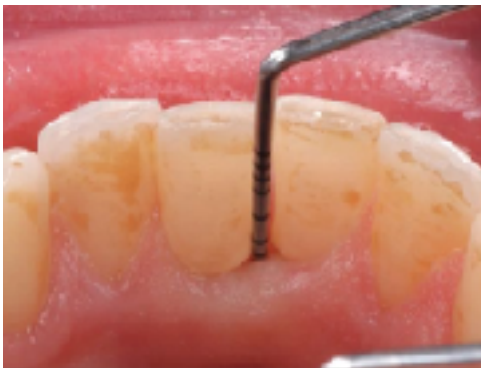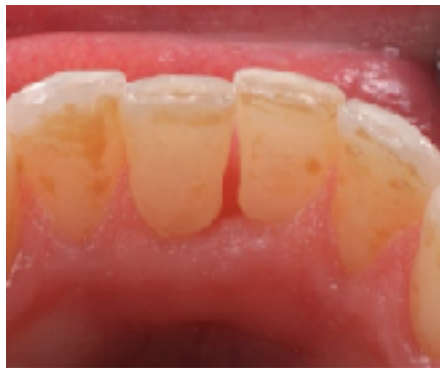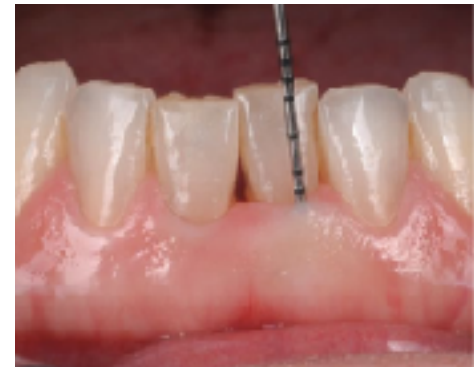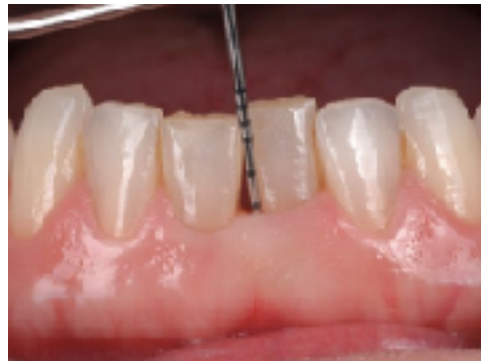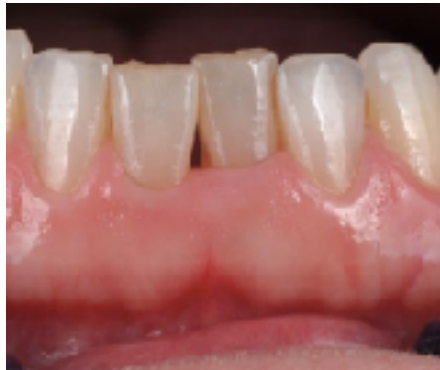31- 41 pockets up to 8 mm with visible loss of attachment

blue<sup>®</sup>m, for the protection of injured periodontal tissue



Initial therapy, oral hygiene reinforcement and blue<sup>®</sup>m oral gel

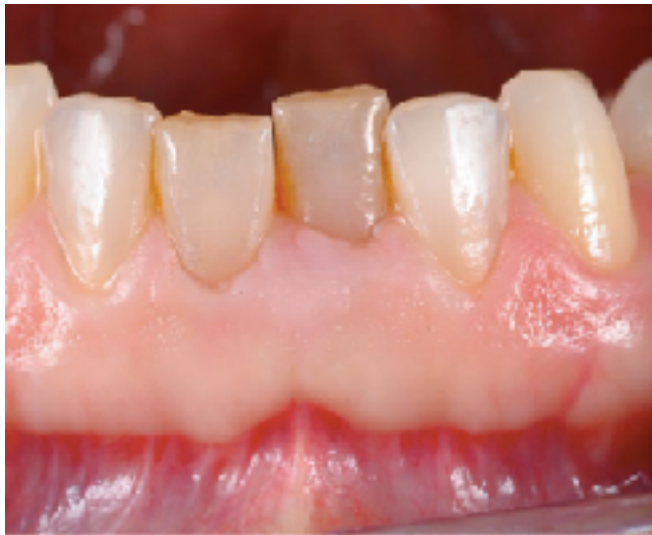blue<sup>®</sup>m, for the protection of injured periodontal tissue



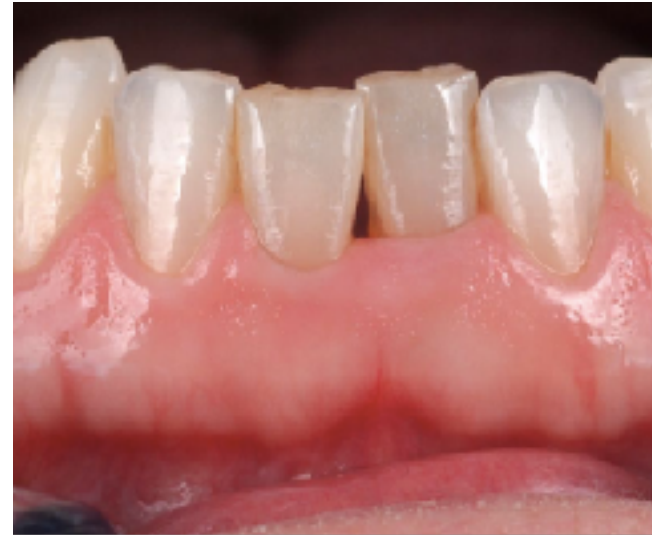Periodontal reevaluation after 6 weeks blue<sup>®</sup>m oral gel

blue<sup>®</sup>m, for the protection of injured periodontal tissue

Comparison 0 and 6 weeks



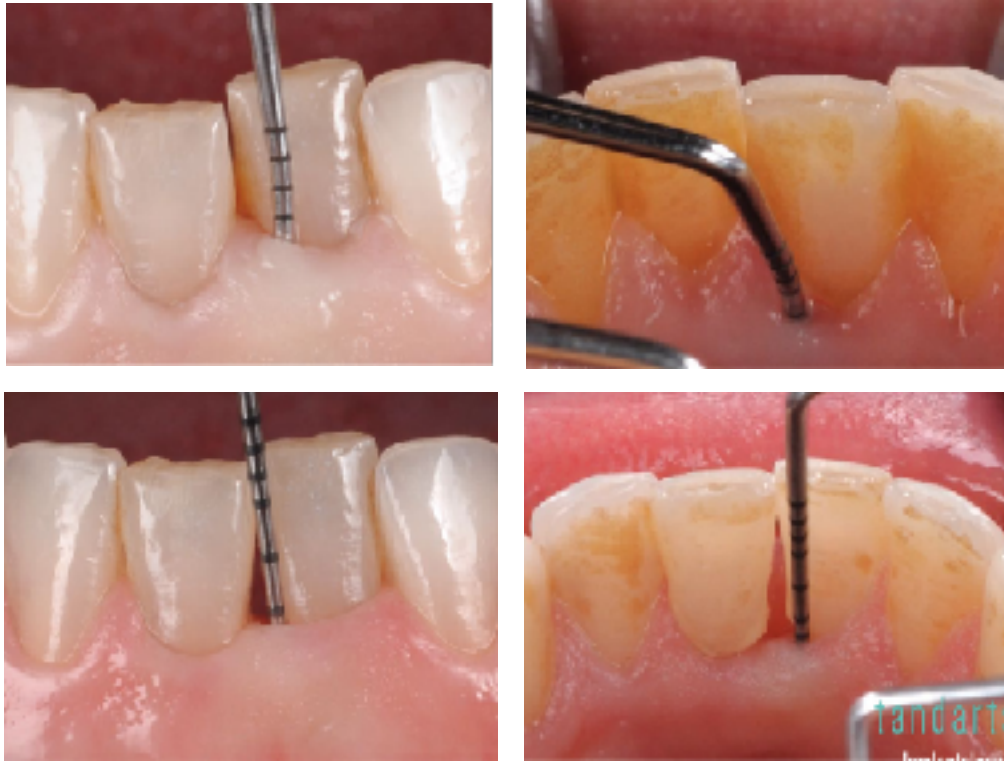
0 weeks



After 6 weeks



blue<sup>®</sup>m, for the protection of injured periodontal tissue



Initial therapy, oral hygiene reinforcement and blue<sup>®</sup>m oral gel